Athlete's ECG: What You Should Not Miss?

A. Moustaghfir MD. Casablanca. Morocco
moustaghfir64@gmail.com

High level sports and "cardiac remodeling"

75% of the theoretical maximum frequency

> 8 to 10 hours per week

Endurance: dilatation

Resistance: hypertrophy

Genetic predisposition?

Difference between regions and races

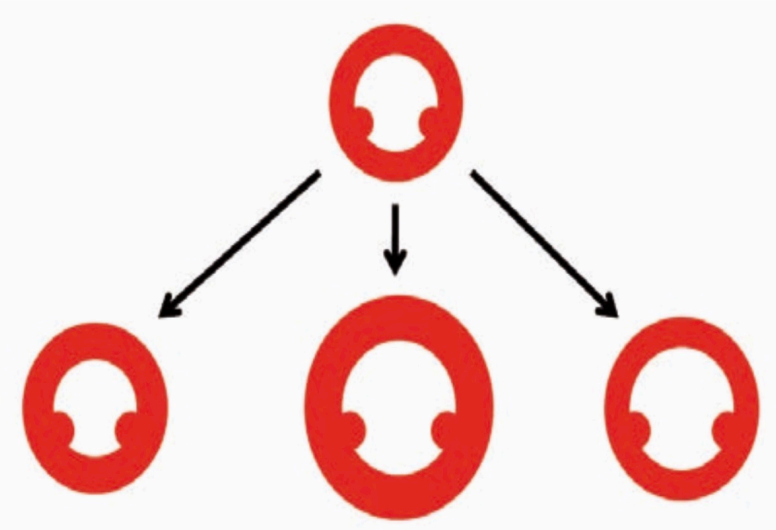

Main etiology: sport doctor

Condition	Description	Recommendation[2,3]
Hypertrophic cardiomyopathy	Autosomal dominant inheritance, generalized or localized hypertrophy of the left ventricle, heart failure, atrial and ventricular arrhythmia, syncope, sudden death	No competitive sports, consider defibrillator implantation
Commotio cordis	Blunt force injury to the chest resulting in ventricular fibrillation	Work-up to rule out underlying heart disease
Anomalous origin of coronary arteries	Variant site of origin of right or left coronary artery, myocardial hypoperfusion, ventricular arrhythmia	No competitive sports, consider referral for surgery if myocardial hypoperfusion is demonstrated
Arrhythmogenic right ventricular dysplasia/cardiomyopathy	Enlargement, dysfunction, and fibro-fatty replacement of the right ventricle, T-wave inversions in leads V1-3 or Epsilon waves on baseline electrocardiogram of some but not all patients, ventricular tachycardia (with left bundle branch like morphology), exertional presyncope, syncope, or sudden death	No competitive sports, defibrillator implantation, beta-blockers or catheter ablation for ventricular tachycardia suppression and shock reduction
Idiopathic ventricular tachycardia	Monomorphic ventricular tachycardia, normal cardiac structure and function	Consider catheter ablation
Atrial fibrillation/flutter	Most common arrhythmia in athletes, associated with endurance training	Competitive sports ok if structural heart disease and rapid ventricular rate are absent, consider catheter ablation
The long QT syndrome	Prolonged and abnormal cardiac repolarization, acquired or inherited	No competitive sports, consider defibrillator implantation
Wolff-Parkinson-White syndrome	Delta wave, atrioventricular reentry tachycardia, sudden death risk due to antegrade conduction of atrial fibrillation	Electrophysiology study and catheter ablation in symptomatic athletes, investigate pathway effective refractory period if asymptomatic
Brugada syndrome	Autosomal dominant inheritance, RSR' and ST segment elevation in right precordial leads, syncope, ventricular fibrillation	No competitive sports, defibrillator implantation
Catecholaminergic polymorphic ventricular tachycardia	Autosomal dominant inheritance, polymorphic ventricular tachycardia or fibrillation triggered by exercise	No competitive sports, defibrillator implantation, beta-blocker to reduce events
The short QT syndrome	Shortened and abnormal cardiac repolarization, atrial fibrillation, sudden death	No competitive sports, consider defibrillator implantation

Comparison of Electrocardiographic Criteria for the Detection of Cardiac Abnormalities in Elite Black and White Athletes

Nabeel Sheikh, MRCP; Michael Papadakis, MRCP; Saqib Ghani, MRCP; Abbas Zaidi, MRCP; Sabiha Gati, MRCP; Paolo Emilio Adami, MD; François Carré, PhD; Frédéric Schnell, PhD; Mathew Wilson, PhD; Paloma Avila, MD; William McKenna, MD, DSc, FESC; Sanjay Sharma, MD, FRCP, FESC (UK)

Background—Recent efforts have focused on improving the specificity of the European Society of Cardiology (ESC) criteria for ECG interpretation in athletes. These criteria are derived predominantly from white athletes (WAs) and do not account for the effect of Afro-Caribbean ethnicity or novel research questioning the relevance of several isolated ECG patterns. We assessed the impact of the ESC criteria, the newly published Seattle criteria, and a group of proposed refined criteria in a large cohort of black athletes (BAs) and WAs.

Methods and Results—Between 2000 and 2012, 1208 BAs were evaluated with history, examination, 12-lead ECG, and further investigations as appropriate. ECGs were retrospectively analyzed according to the ESC recommendations, Seattle criteria, and proposed refined criteria which exclude several specific ECG patterns when present in isolation. All 3 criteria were also applied to 4297 WAs and 103 young athletes with hypertrophic cardiomyopathy. The ESC recommendations raised suspicion of a cardiac abnormality in 40.4% of BAs and 16.2% of WAs. The Seattle criteria reduced abnormal ECGs to 18.4% in BAs and 7.1% in WAs. The refined criteria further reduced abnormal ECGs to 11.5% in BAs and 5.3% in WAs. All 3 criteria identified 98.1% of athletes with hypertrophic cardiomyopathy. Compared with ESC recommendations, the refined criteria improved specificity from 40.3% to 84.2% in BAs and from 73.8% to 94.1% in WAs without compromising the sensitivity of the ECG in detecting pathology.

Conclusion—Refinement of current ECG screening criteria has the potential to significantly reduce the burden of false-positive ECGs in athletes, particularly BAs. **(*Circulation*. 2014;129:1637-1649.)**

Key Words: cardiomyopathies ■ echocardiography ■ electrocardiography ■ ethnic groups ■ exercise ■ hypertrophy ■ mass screening

Comparison of Electrocardiographic Criteria for the Detection of Cardiac Abnormalities in Elite Black and White Athletes

Nabeel Sheikh, MRCP; Michael Papadakis, MRCP; Saqib Ghani, MRCP; Abbas Zaidi, MRCP; Sabiha Gati, MRCP; Paolo Emilio Adami, MD; François Carré, PhD; Frédéric Schnell, PhD; Mathew Wilson, PhD; Paloma Avila, MD; William McKenna, MD, DSc, FESC; Sanjay Sharma, MD, FRCP, FESC (UK)

Refined Criteria Training Related Normal Variants
*Not Warranting Further Investigation**

- Sinus bradycardia
- First-degree AV block
- Incomplete RBBB
- Early repolarisation
- Isolated QRS voltage criteria for LVH

Refined Criteria Borderline Variants
Potentially Warranting Further Investigation

- Left atrial enlargement
- Right atrial enlargement
- Left axis deviation
- Right axis deviation
- Right ventricular hypertrophy
- TWI up to V4 in BAs†

Refined Criteria Training Unrelated Changes
Warranting Further Investigation

- ST-segment depression
- Pathological Q-waves
- Ventricular pre-excitation
- TWI beyond V1 in WAs beyond V4 in BAs
- Complete LBBB or RBBB
- QTc ≥470 ms in males ≥480 ms in females
- Brugada-like ER
- Atrial or vent. arrhythmias
- ≥2 PVCs per 10 sec tracing

*If present in **ISOLATION****

*If **TWO OR MORE** present*

Circulation. 2014;129:1637-1649.

Athlete's heart: differences between races

Circulation. 2014;129:1637-1649.

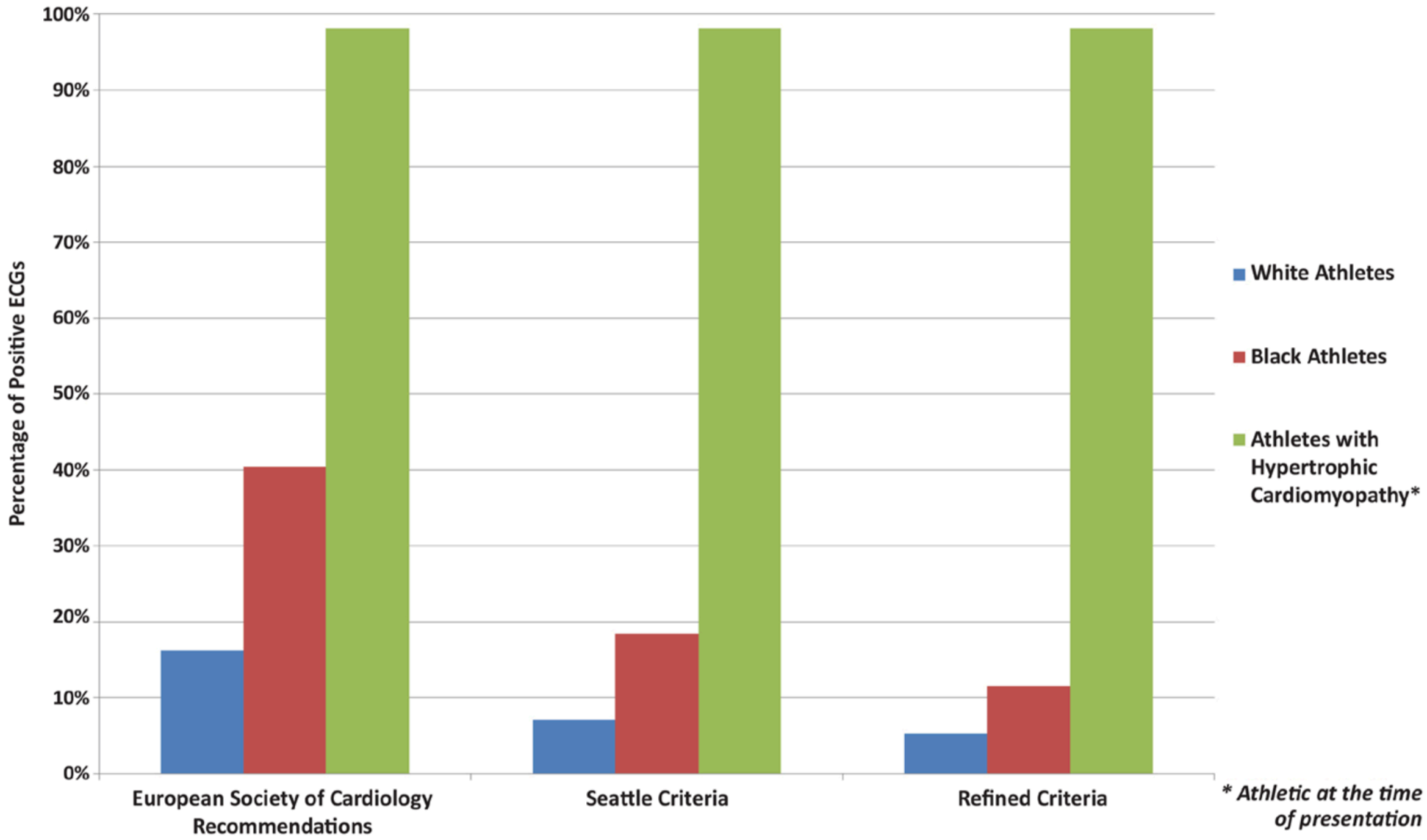

Figure 2. The number of positive ECGs produced by the 3 different ECG screening criteria.

Athlete's heart: differences between races

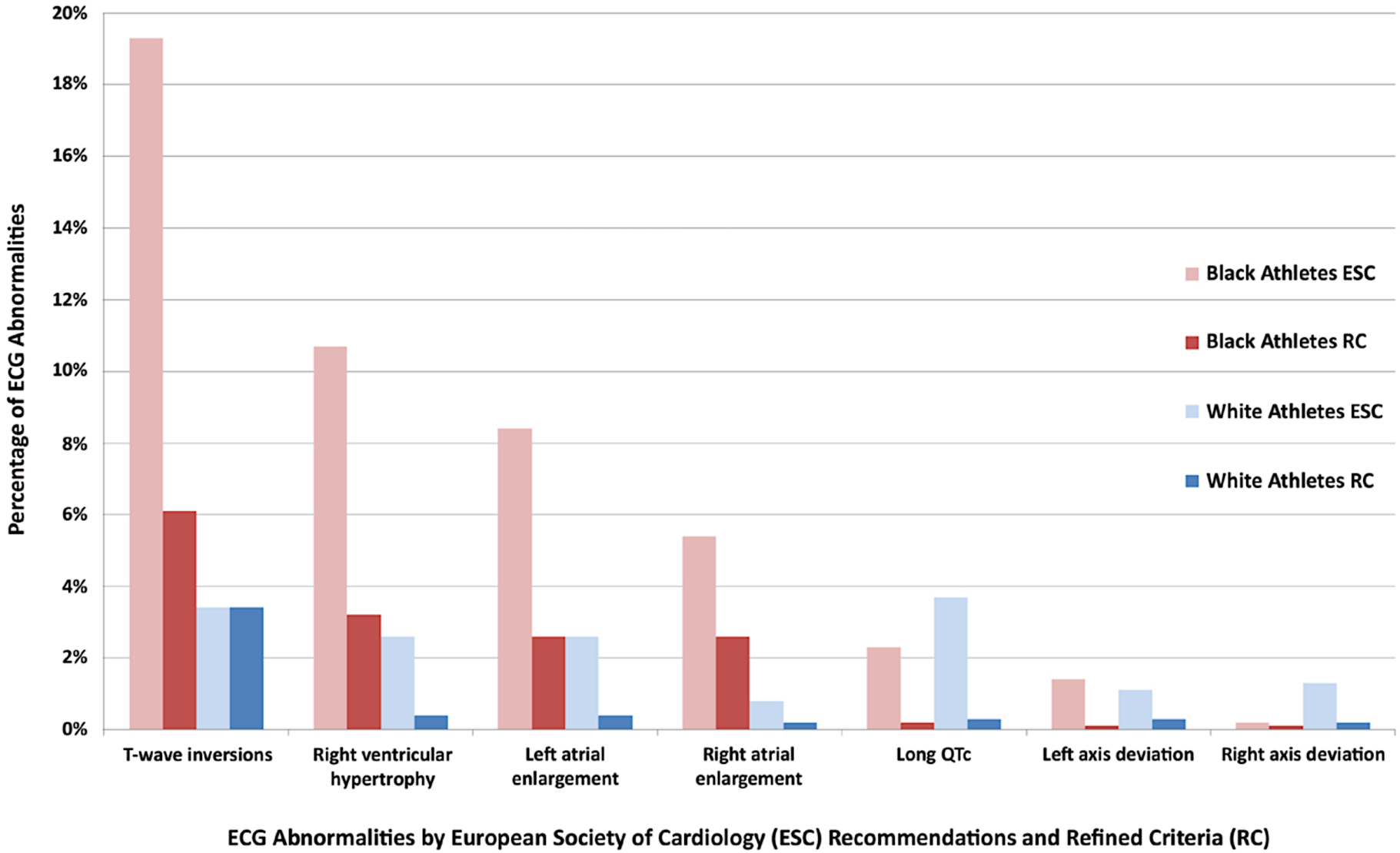

Circulation. 2014;129:1637-1649.

International recommendations for electrocardiographic interpretation in athletes

Sharma S et all. European Heart Journal. 2018; 39:1466-1480

Normal ECG Findings

- Increased QRS voltage for LVH or RVH
- Incomplete RBBB
- Early repolarization/ST segment elevation
- ST elevation followed by T wave inversion V1-V4 in black athletes
- T wave inversion V1-V3 < age 16 years
- Sinus bradycardia or arrhythmia
- Ectopic atrial or junctional rhythm
- 1° AV block
- Mobitz Type I 2° AV block

Short PR without Preexcitation

Borderline ECG Findings

- Left axis deviation
- Left atrial enlargement
- Right axis deviation
- Right atrial enlargement
- Complete RBBB

Abnormal ECG Findings

- T wave inversion
- ST segment depression
- Pathologic Q waves
- Complete LBBB
- QRS ≥ 140 ms duration
- Epsilon wave
- Ventricular pre-excitation
- Prolonged QT interval
- Brugada Type 1 pattern
- Profound sinus bradycardia < 30 bpm
- PR interval ≥ 400 ms
- Mobitz Type II 2° AV block
- 3° AV block
- ≥ 2 PVCs
- Atrial tachyarrhythmias
- Ventricular arrhythmias

In isolation

2 or more

No further evaluation required in asymptomatic athletes with no family history of inherited cardiac disease or SCD

Further evaluation required to investigate for pathologic cardiovascular disorders associated with SCD in athletes

normal ECG

HVG , Early repolarization

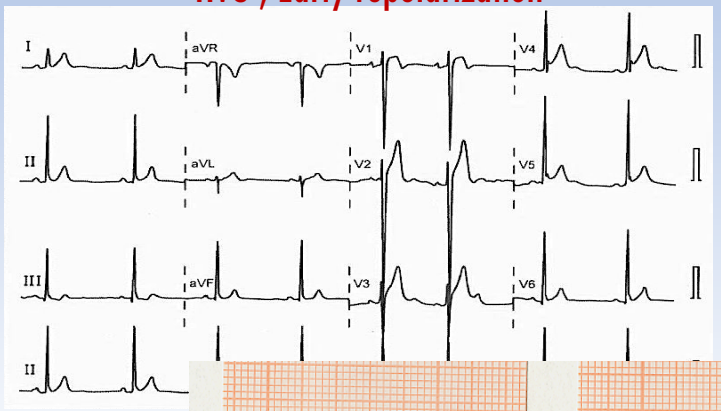

Incomplete RBBB

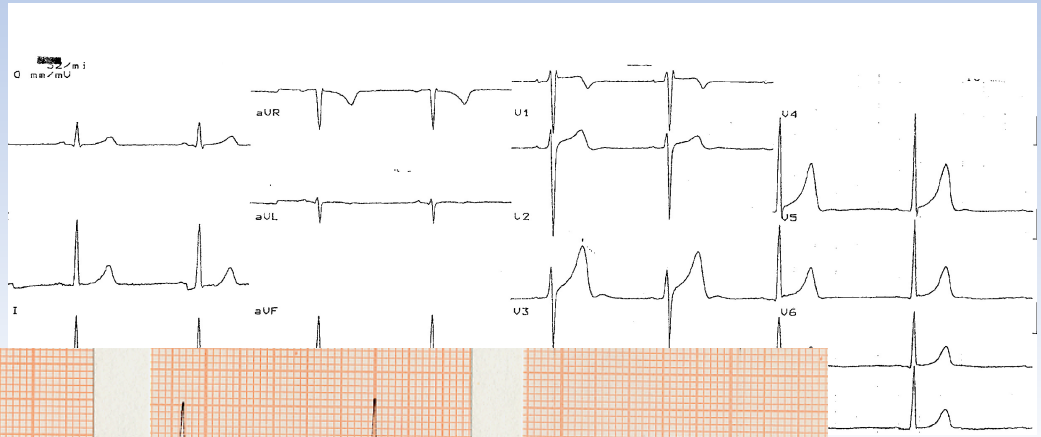

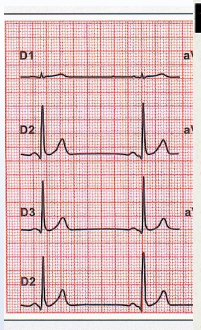

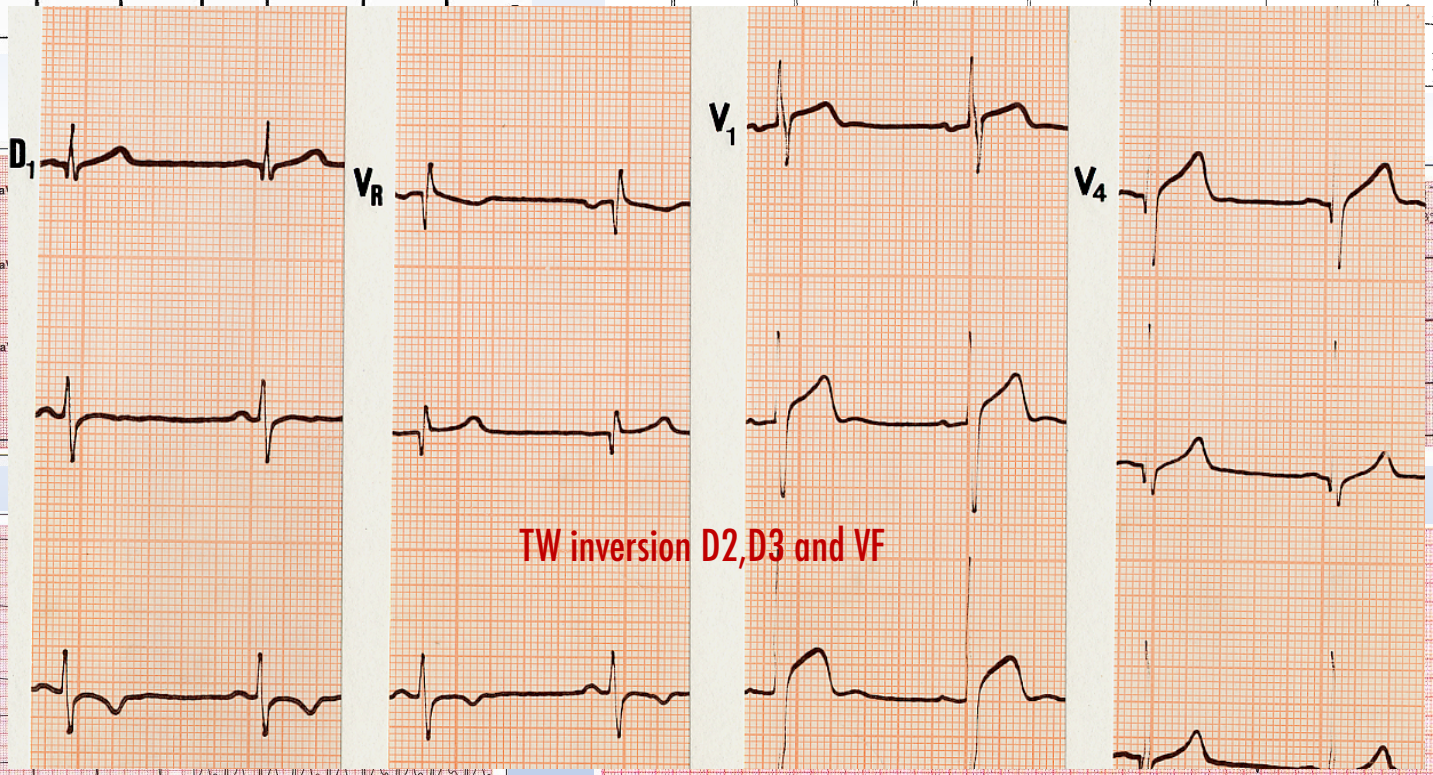

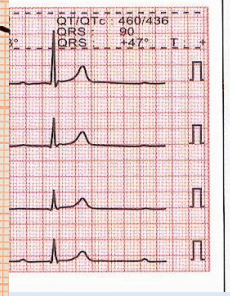

TW inversion D2,D3 and VF

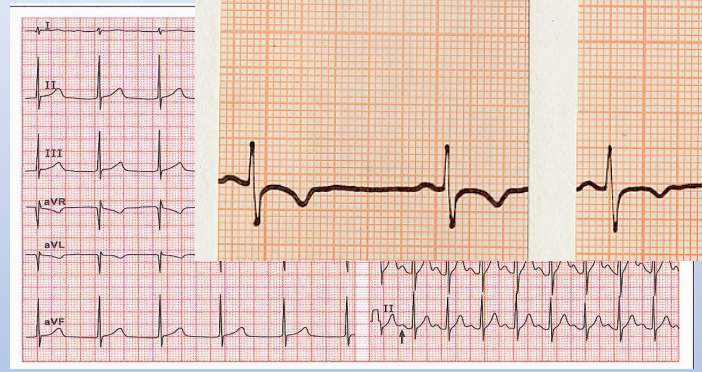

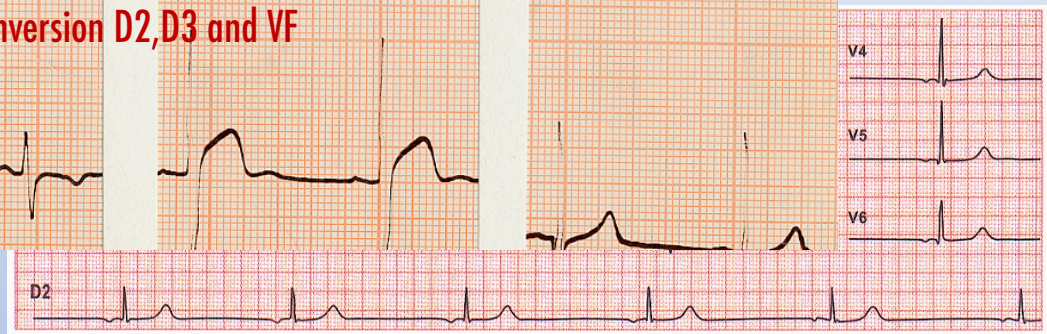

Questionable ECG

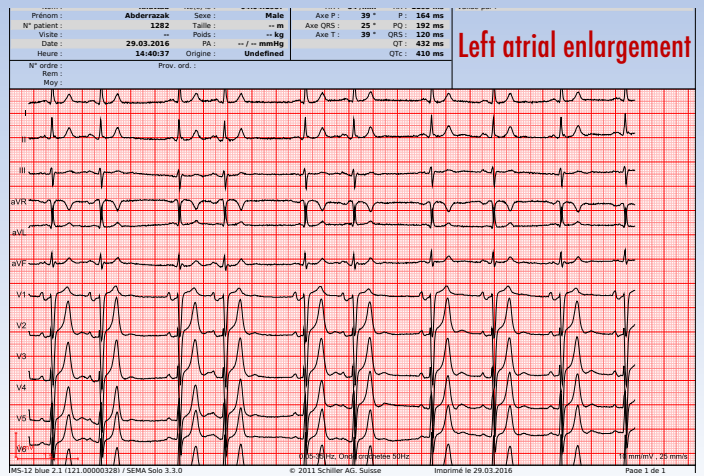

Left atrial enlargement

Right atrial enlargement

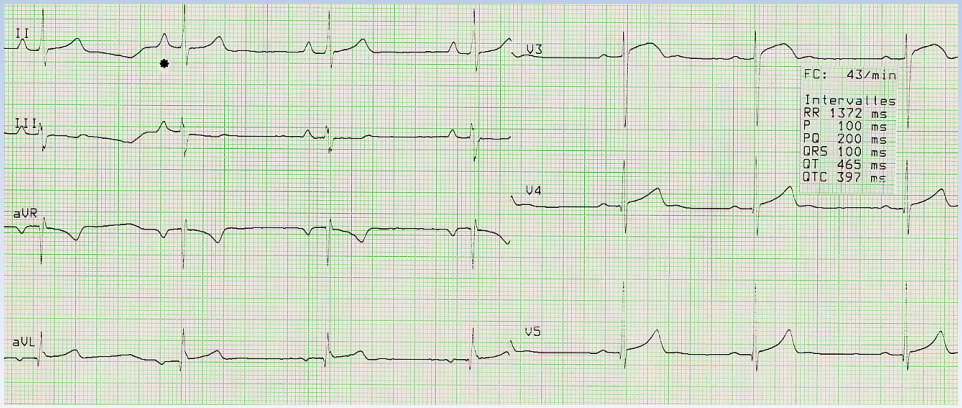

TWI up to V4 in BAs

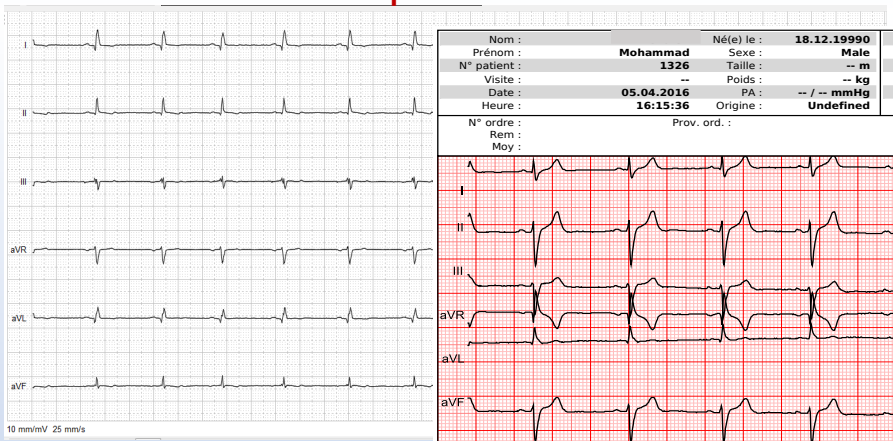

Right ventricular hypertrophy

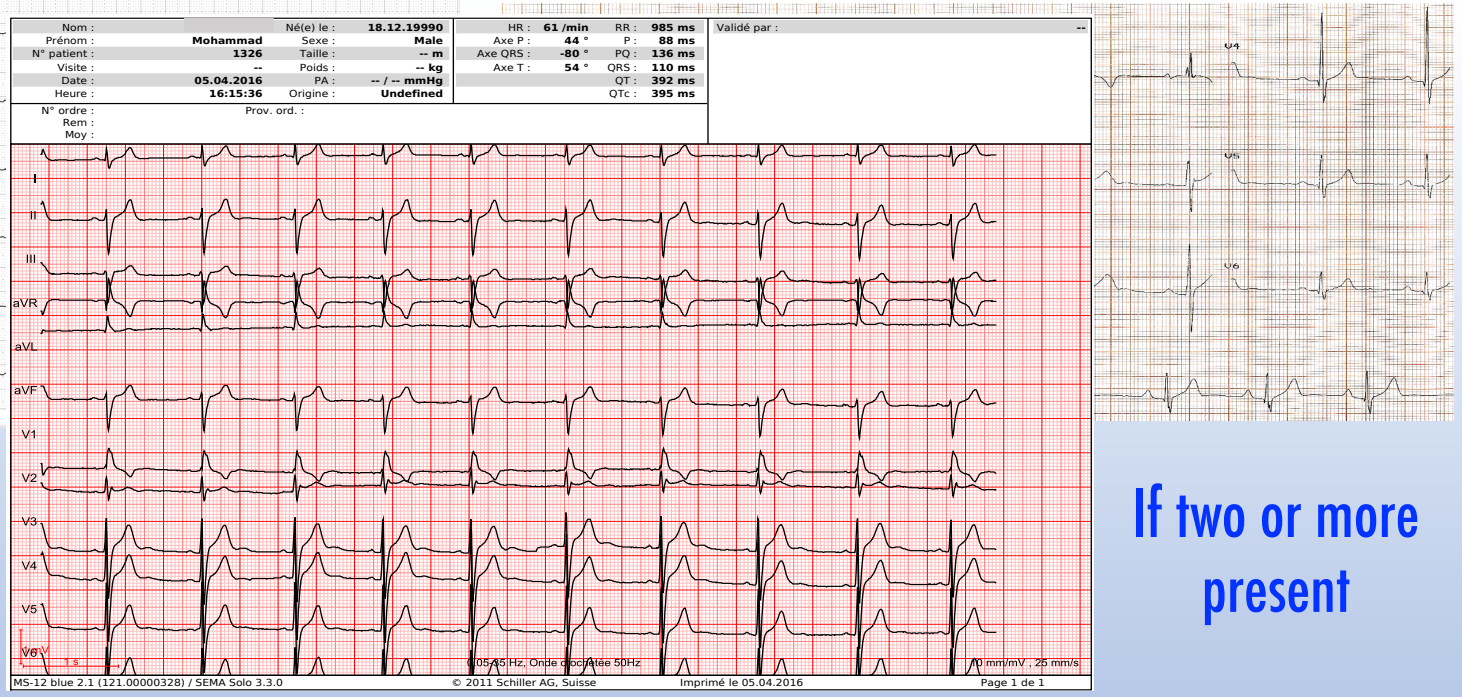

Left or right axis deviation

If two or more present

ECG abnormalities and sport

Sports doctors And ECG

1. High degree conduction disorders
   - Profound sinus bradycardia
   - Profound 1°atrioventricular block >400 ms
   - Mobitz Type II 2° atrioventricular block
   - 3° atrioventricular block
2. Depolarization disorders
   - WPW
   - LBBB
   - Anormal Q waves
3. Repolarization disorders
   - ST abnormalities
   - T wave inversion: V5,V6, D1,VL
   - J Wave syndromes
   - QT syndrome
4. Premature Beat
   - atrial
   - ventricular +++

1. High degree conduction disorders

Disturbing ECG

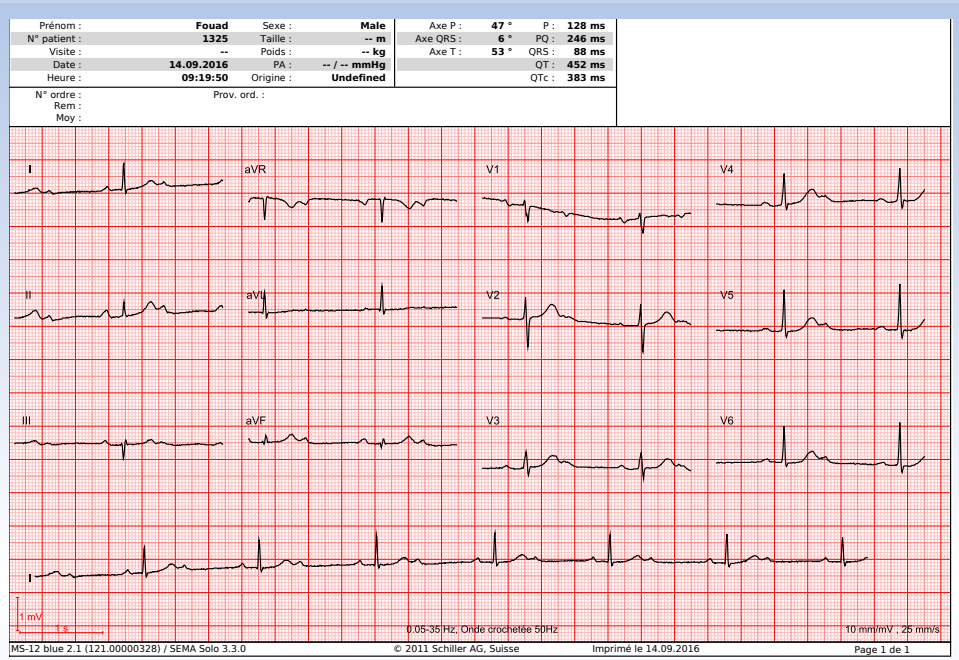

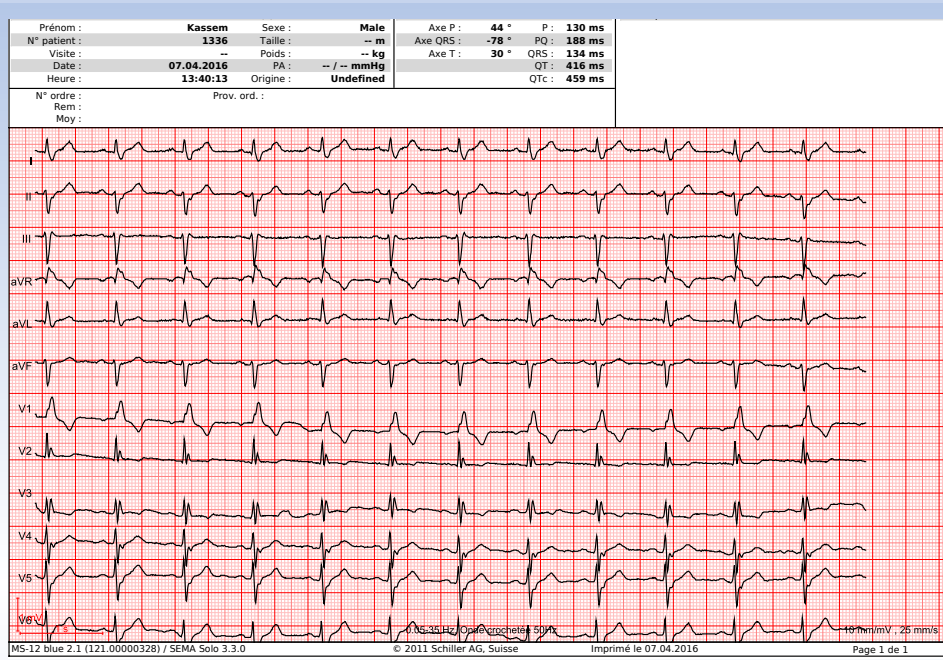

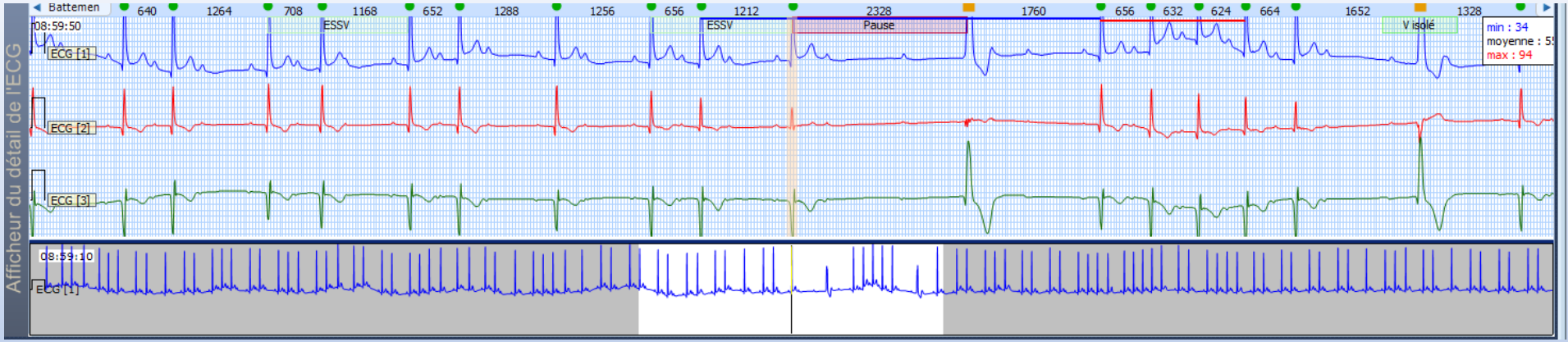

Second AVB Mobitz 1

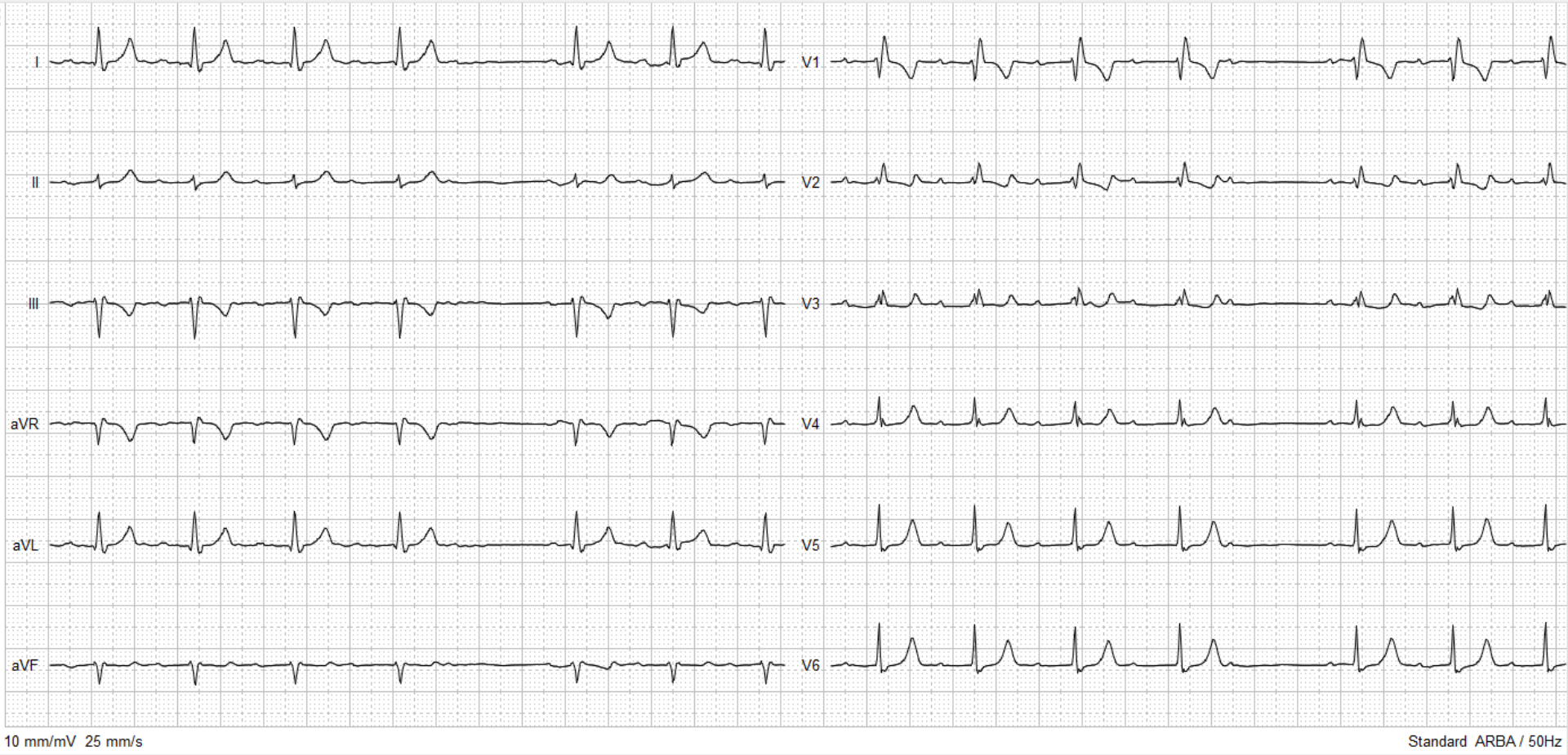

Depolarization disorders

WPW syndrome

Pr Abdelhamid Moustaghfir
Cabinet de cardiologie à orientation rythmologique

Nom :		Né(e) le :	28.07.1992
Prénom :	Adil	Sexe :	Male
N° patient :	98	Taille :	-- m
Visite :	--	Poids :	-- kg
Date :	05.08.2015	PA :	-- / -- mmHg
Heure :	11:28:07	Origine :	Undefined
N° ordre :		Prov. ord. :	

HR :	62 /min	RR :	974 ms
Axe P :	90 °	P :	66 ms
Axe QRS :	27 °	PQ :	84 ms
Axe T :	97 °	QRS :	164 ms
		QT :	430 ms
		QTc :	437 ms

Rem :

Moy :

Validé par : --

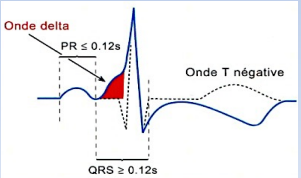

MS-12 blue 2.1 (121.00000328) / SEMA Solo 3.3.0 © 2011 Schiller AG, Suisse Imprimé le 05.08.2015 Page 1 de 1

WPW and sudden death

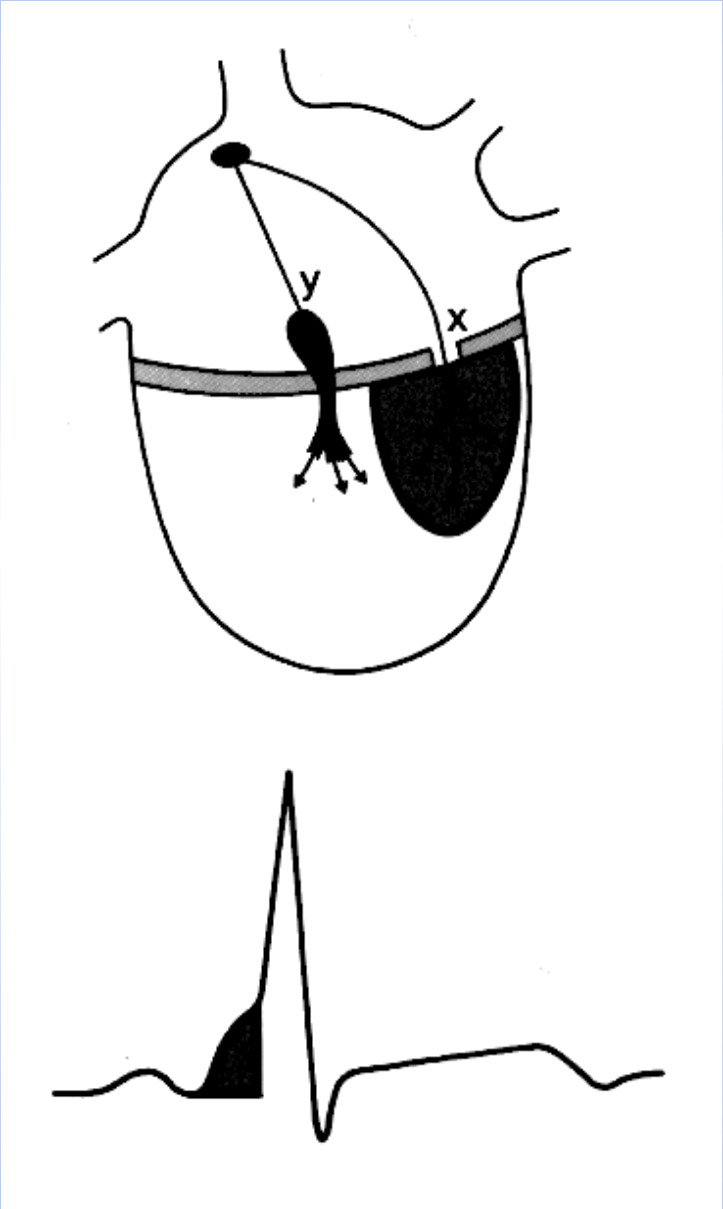

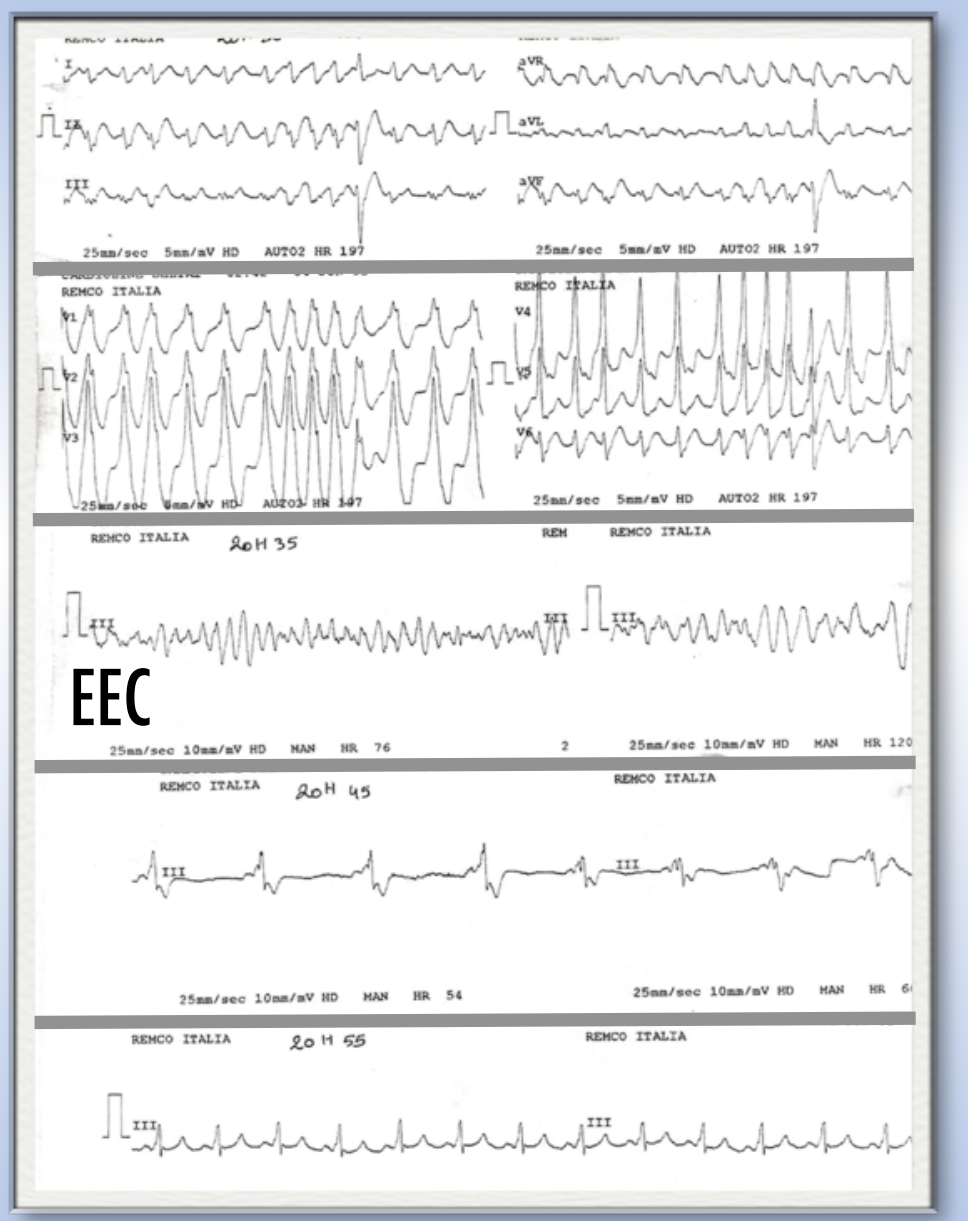

Left bundle block

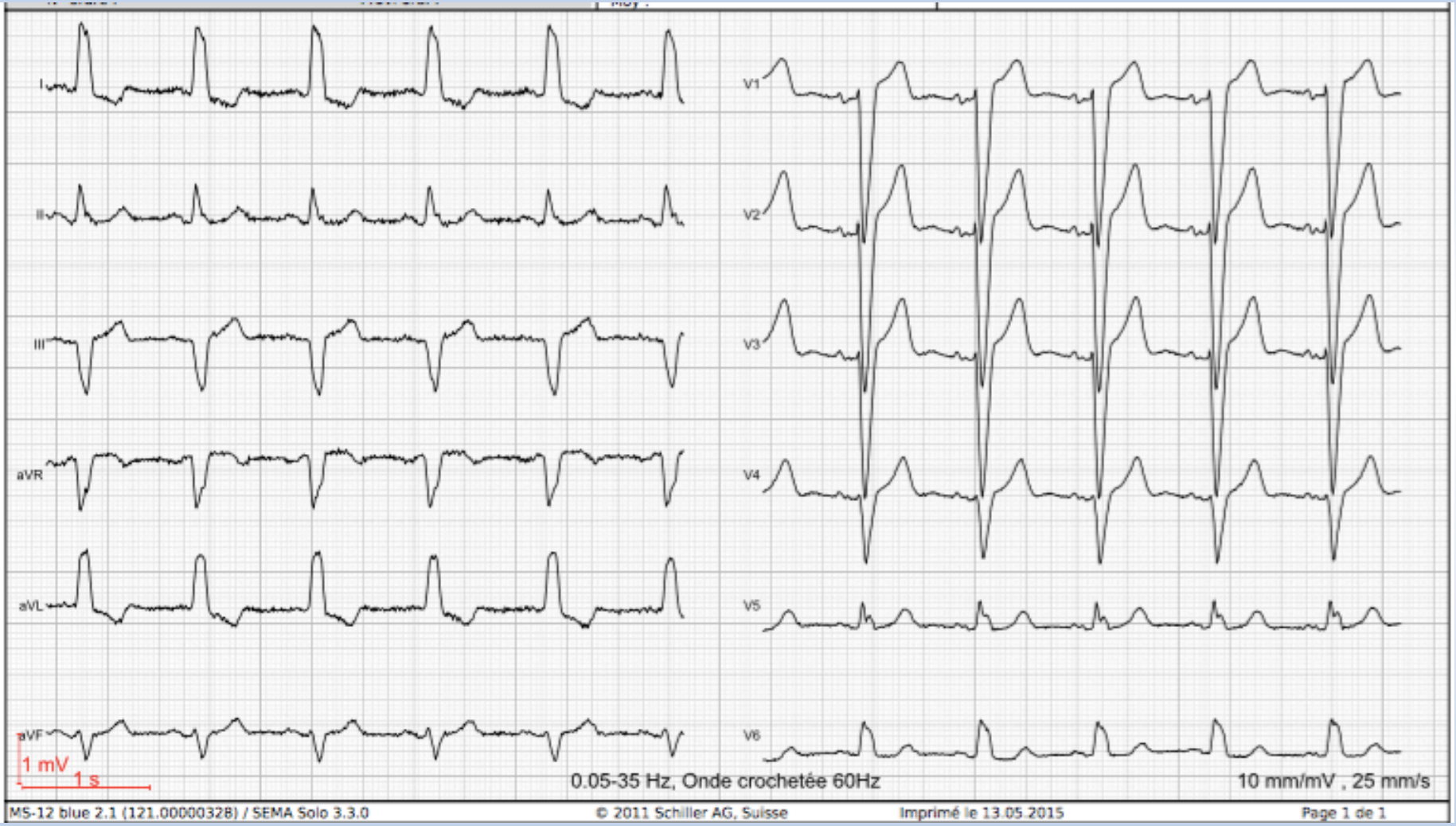

RBBB with Wide QRS

Prénom :	**Hassan**	Sexe :	**Male**	Axe P :	**37 °**	P :	**124 ms**
N° patient :	**1507**	Taille :	**-- m**	Axe QRS :	**-11 °**	PQ :	**152 ms**
Visite :	**--**	Poids :	**-- kg**	Axe T :	**20 °**	QRS :	**162 ms**
Date :	**09.05.2016**	PA :	**-- / -- mmHg**			QT :	**398 ms**
Heure :	**15:46:06**	Origine :	**Undefined**			QTc :	**427 ms**

N° ordre :
Prov. ord. :
Rem :
Moy :

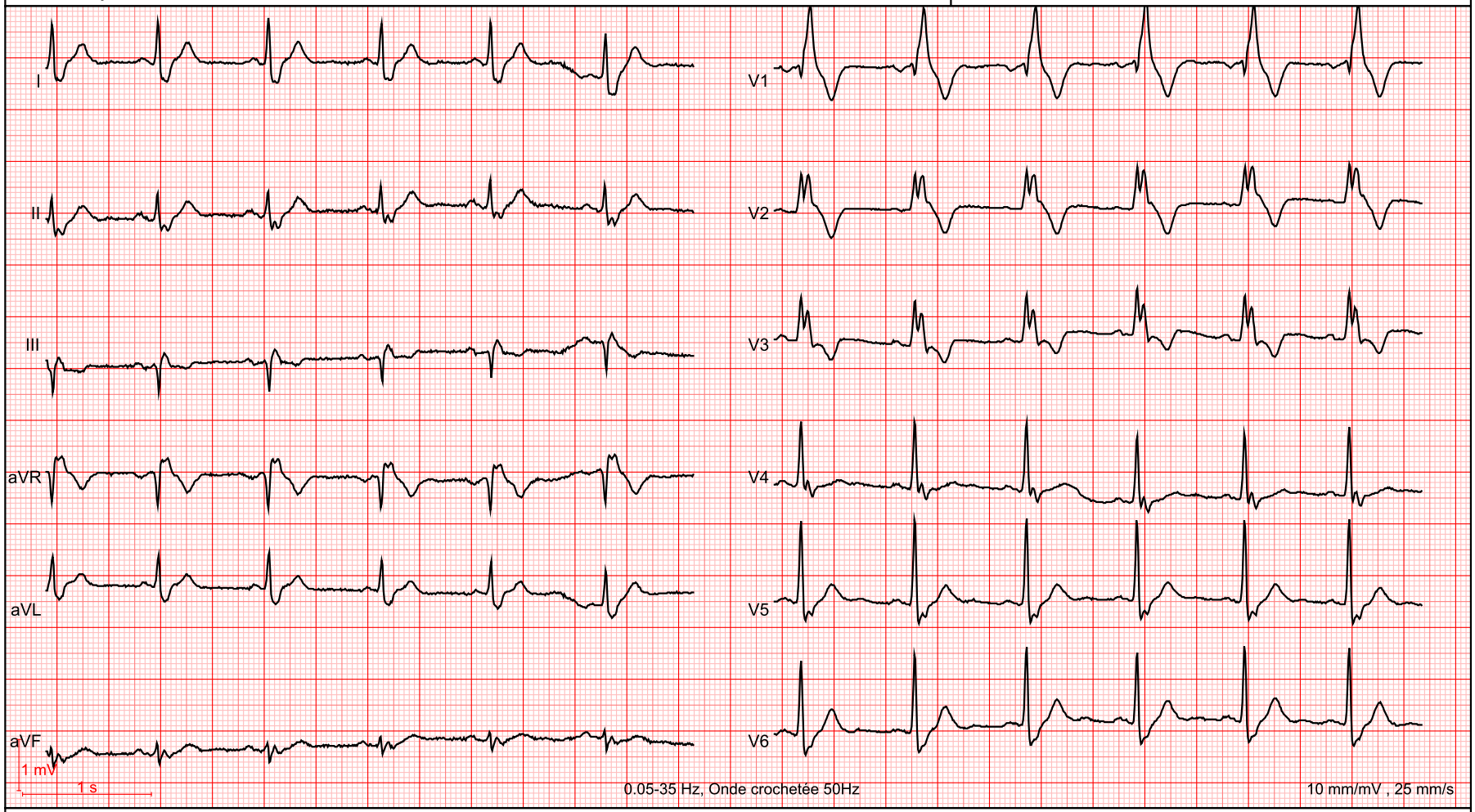

Short P-QRS

Nom :		Né(e) le :	09.03.2005	HR :	56 /min	RR :	1063 ms	Validé par : --
Prénom :	Mohammed	Sexe :	Male	Axe P :	-- °	P :	-- ms	
N° patient :	1993	Taille :	-- m	Axe QRS :	52 °	PQ :	-- ms	
Visite :	--	Poids :	-- kg	Axe T :	43 °	QRS :	92 ms	
Date :	19.08.2016	PA :	-- / -- mmHg			QT :	454 ms	
Heure :	15:48:32	Origine :	Undefined			QTc :	439 ms	

N° ordre : Prov. ord. :
Rem :
Moy :

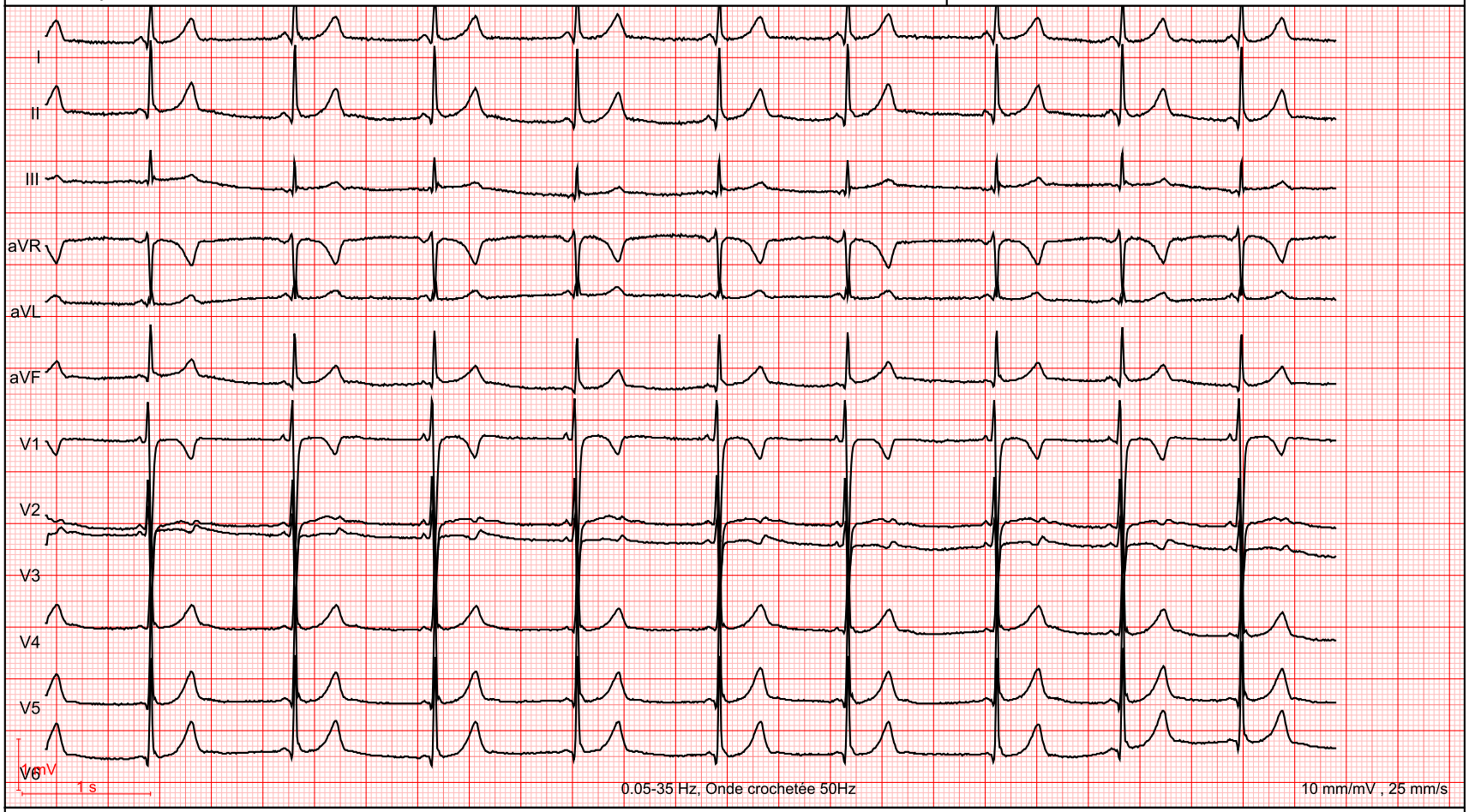

MS-12 blue 2.1 (121.00000328) / SEMA Solo 3.3.0 © 2011 Schiller AG, Suisse Imprimé le 19.08.2016 Page 1 de 1

Repolarization disorders

Under offset ST segment

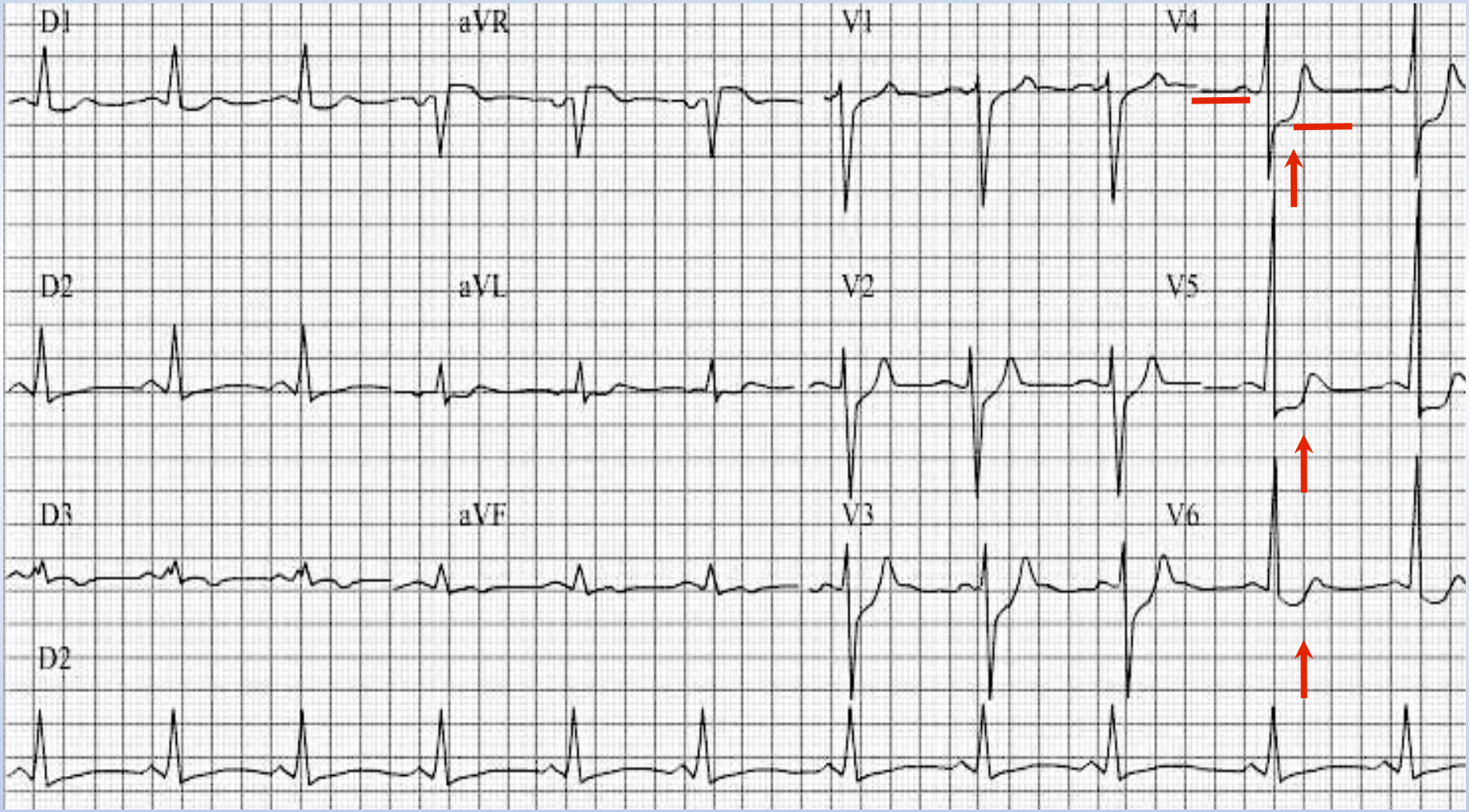

MHC and negative T waves

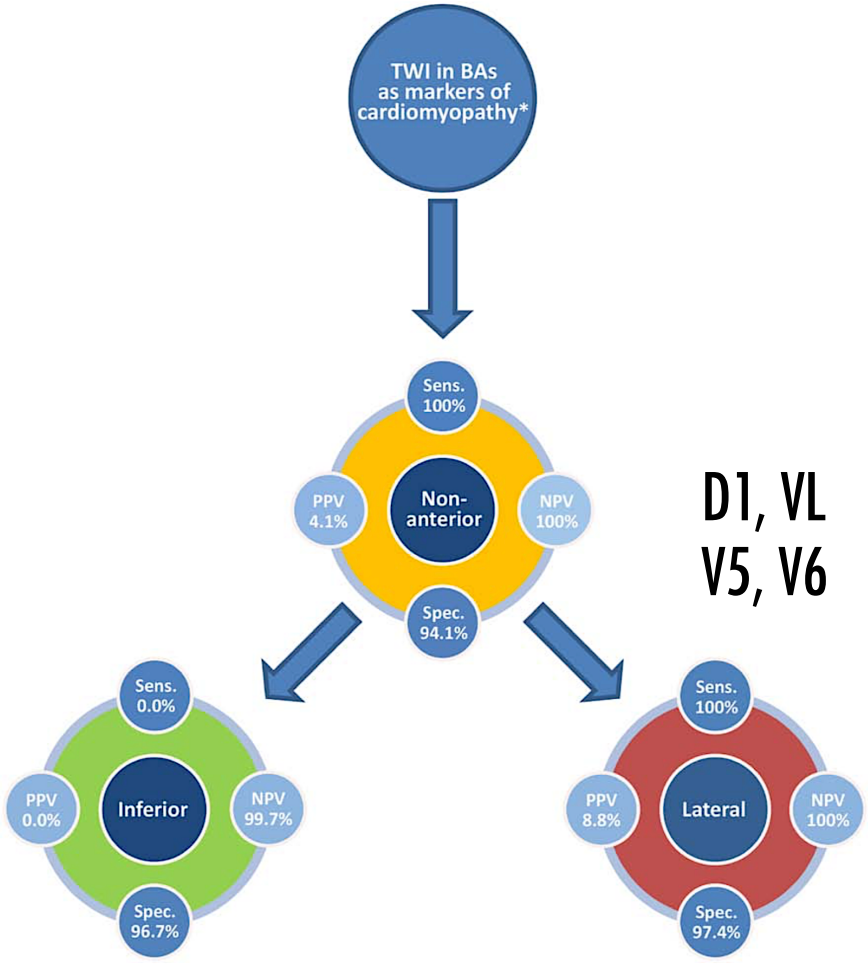

Circulation. 2014;129:1637-1649.

D1, VL
V5, V6

D1, VL, V5 and V6: Predictive values of T-wave inversion for MHC in black athletes.

ST segment and J wave

Prenom :	Bouazza	Sexe :	Male	Axe P :	51 °	P :	114 ms
N° patient :	1502	Taille :	-- m	Axe QRS :	12 °	PQ :	154 ms
Visite :	--	Poids :	-- kg	Axe T :	129 °	QRS :	94 ms
Date :	27.05.2016	PA :	-- / -- mmHg			QT :	422 ms
Heure :	18:04:05	Origine :	Undefined			QTc :	456 ms

N° ordre :
Rem :
Moy :
Prov. ord. :

Acute IM

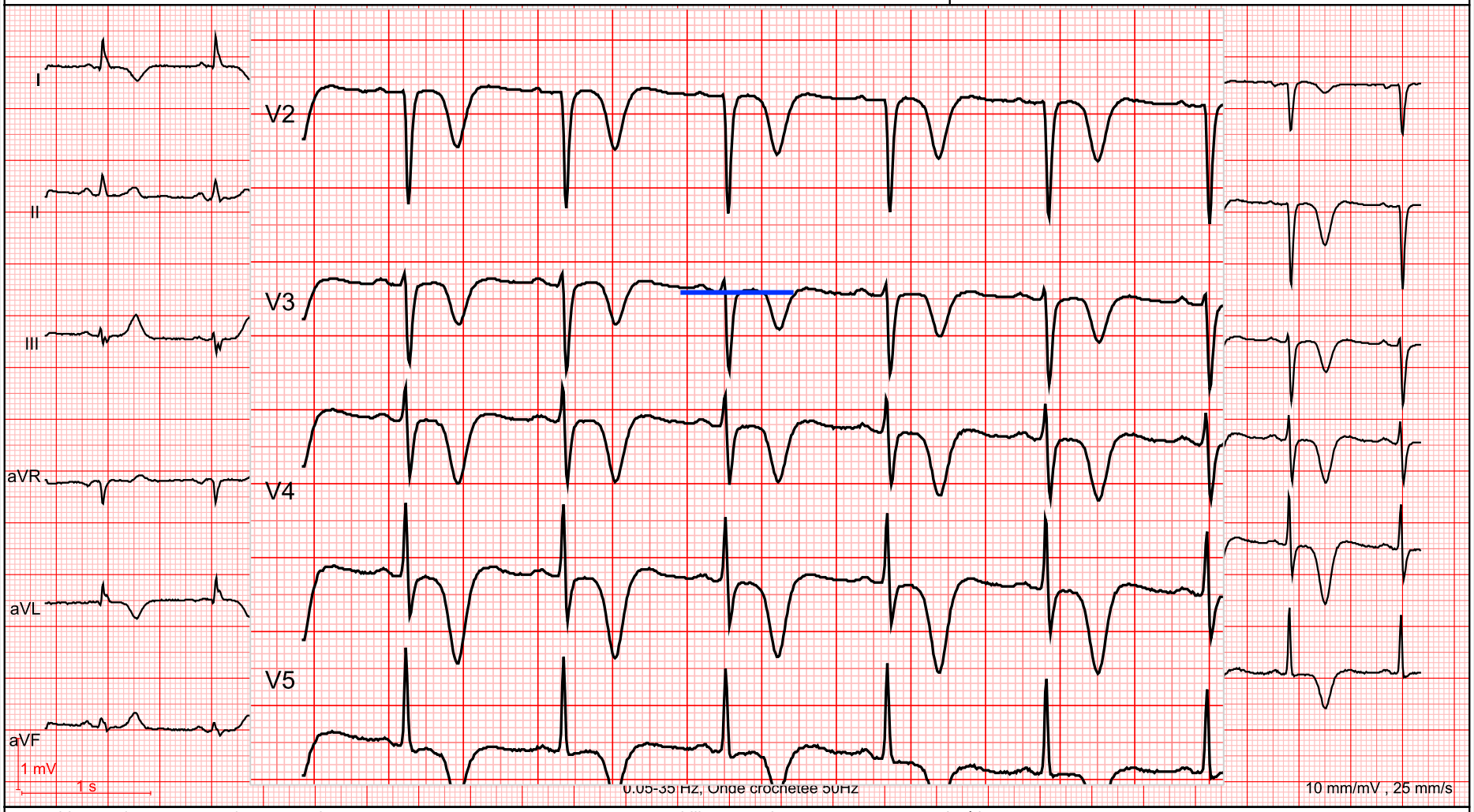

MS-12 blue 2.1 (121.00000328) / SEMA Solo 3.3.0 © 2011 Schiller AG, Suisse Imprimé le 27.05.2016 Page 1 de 1

ARVD and surface ECG

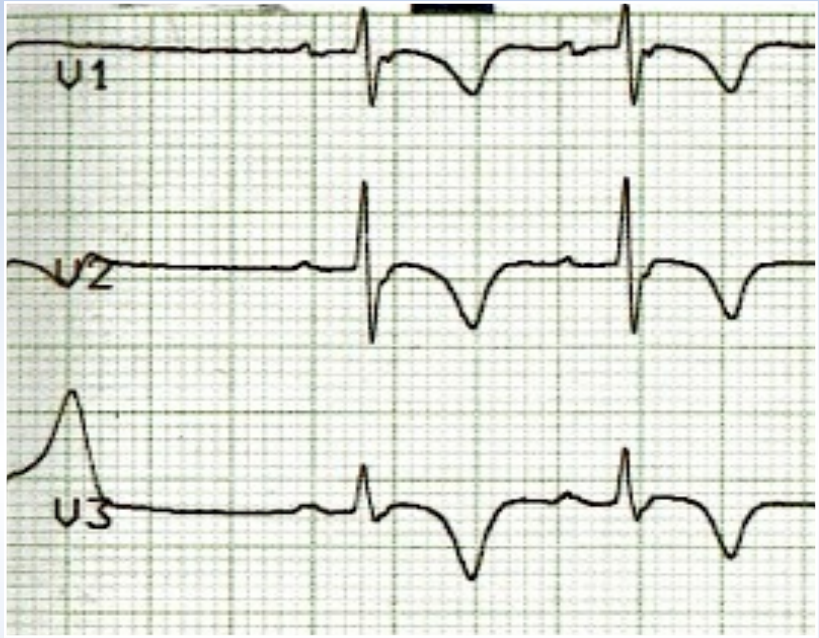

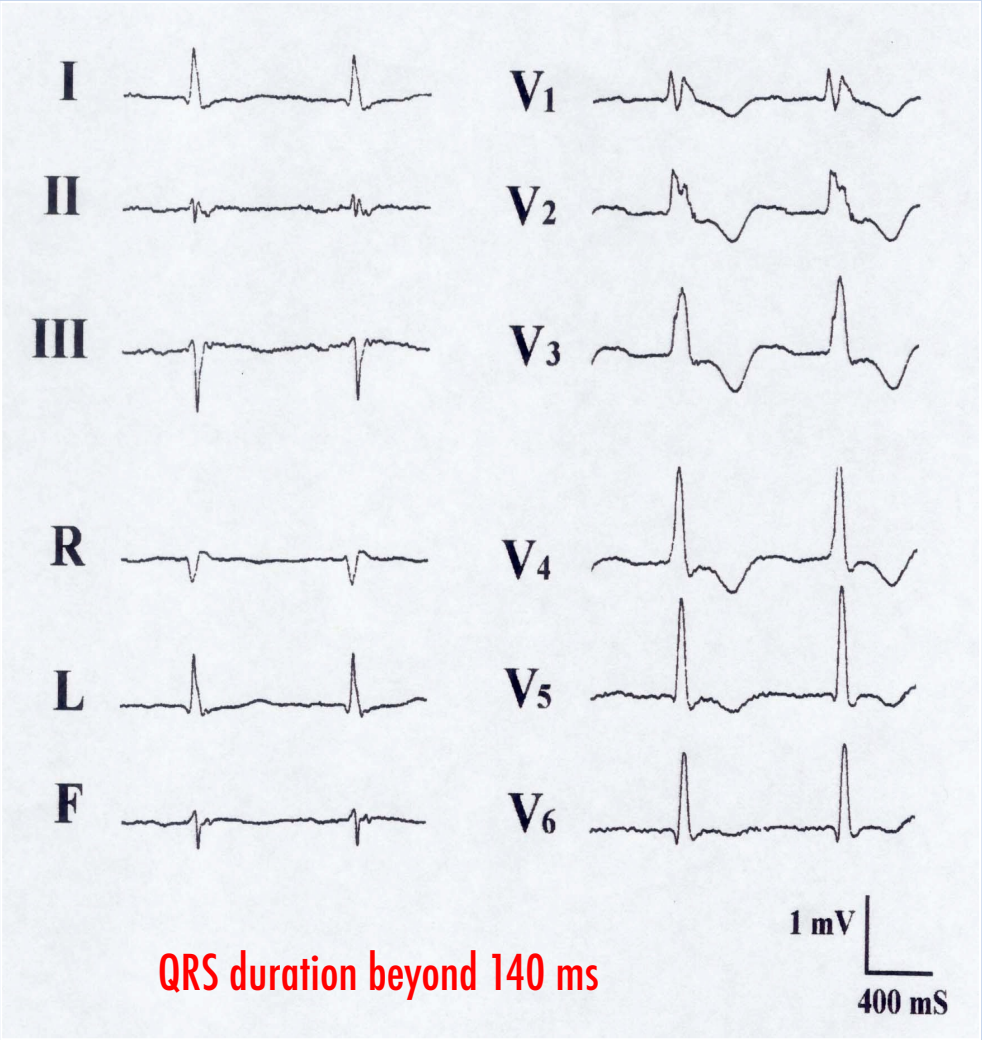

Rarely normal ECG in proven DAVD

ARVD

Nom :		Né(e) le :	**11.11.1982**	HR :	**71 /min**	RR :	**843 ms**	Validé par : **--**
Prénom :	**Abdelhamid**	Sexe :	**Male**	Axe P :	**11 °**	P :	**80 ms**	
N° patient :	**1460**	Taille :	**-- m**	Axe QRS :	**14 °**	PQ :	**154 ms**	
Visite :	**--**	Poids :	**-- kg**	Axe T :	**186 °**	QRS :	**106 ms**	
Date :	**07.11.2016**	PA :	**-- / -- mmHg**			QT :	**454 ms**	
Heure :	**15:51:54**	Origine :	**Undefined**			QTc :	**494 ms**	

N° ordre :
Prov. ord. :
Rem :
Moy :

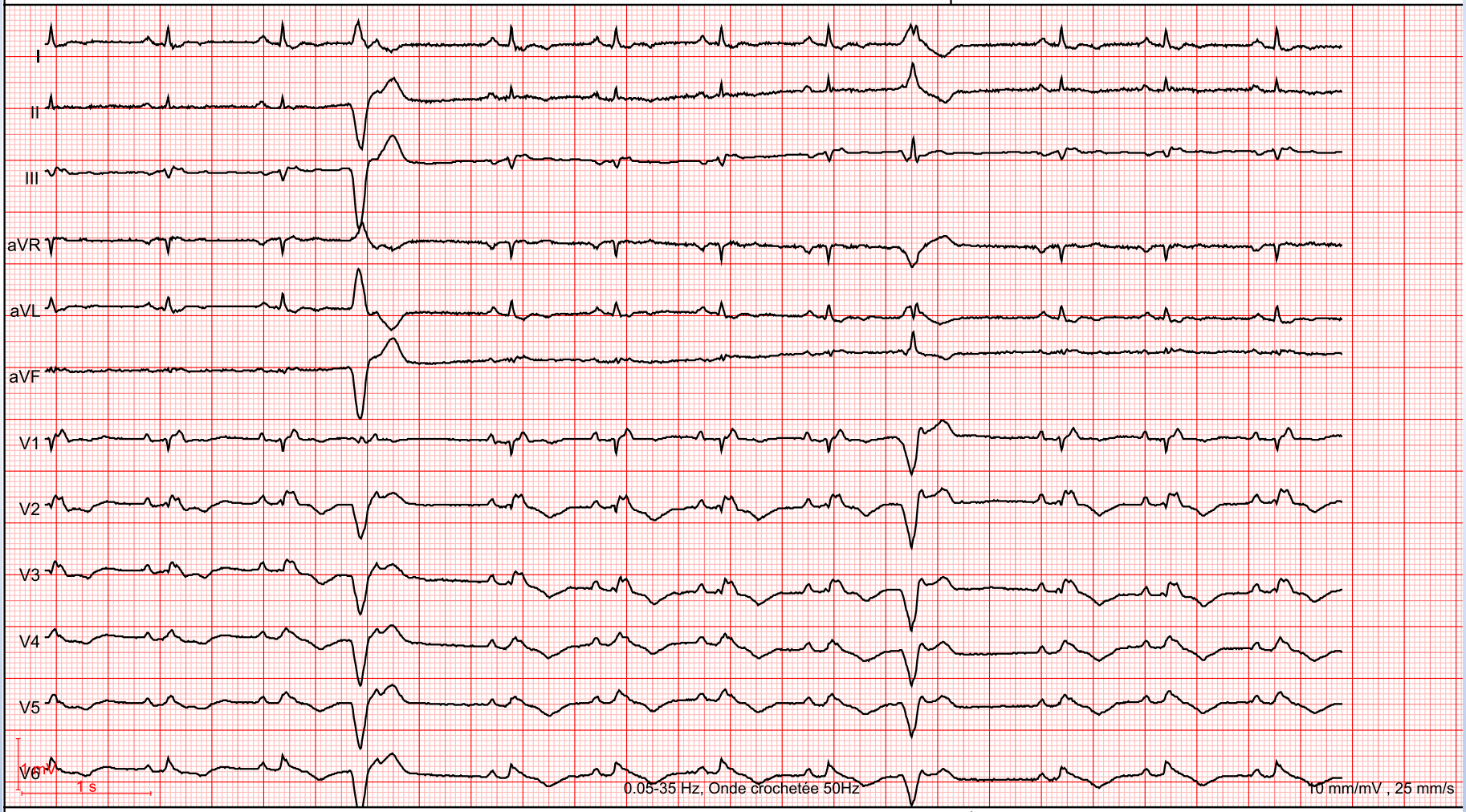

MS-12 blue 2.1 (121.00000331) / SEMA Solo 3.3.0 © 2011 Schiller AG, Suisse Imprimé le 07.11.2016 Page 1 de 1

Brugada syndrome

Eight men for 1 woman

Syncope and sudden TV or FV death, often in a vagal setting

Higher incidence of SV tachycardias

First symptoms between 20 and 30 years old, but also rare cases described in children

fast sodium current inhibitors

Unmasking or worsening ECG abnormalities

Intravenous injection on 5 mn of 1 mg / kg of ajmaline or on 10 mn of 2 mg / kg of flecainide

Perform an ECG before, during and every 5 mn for 20 mn

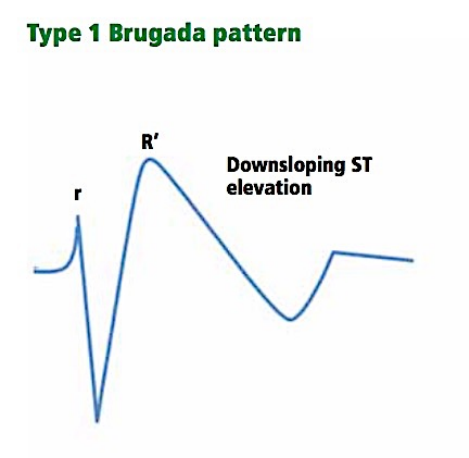

Miyazaki et al. J Am Coll Cardiol 1996
Eckardt et al. J Cardiovasc Electrophysiol 2001

Brugada syndrome type 1

Prénom :	**Khadija**	Sexe :	**Female**	Axe P :	**34 °**	P :	**98 ms**
N° patient :	**1262**	Taille :	**-- m**	Axe QRS :	**62 °**	PQ :	**150 ms**
Visite :	**--**	Poids :	**-- kg**	Axe T :	**77 °**	QRS :	**114 ms**
Date :	**25.03.2016**	PA :	**-- / -- mmHg**			QT :	**380 ms**
Heure :	**16:01:08**	Origine :	**Undefined**			QTc :	**428 ms**

N° ordre :
Rem :
Moy :
Prov. ord. :

3ème EIC

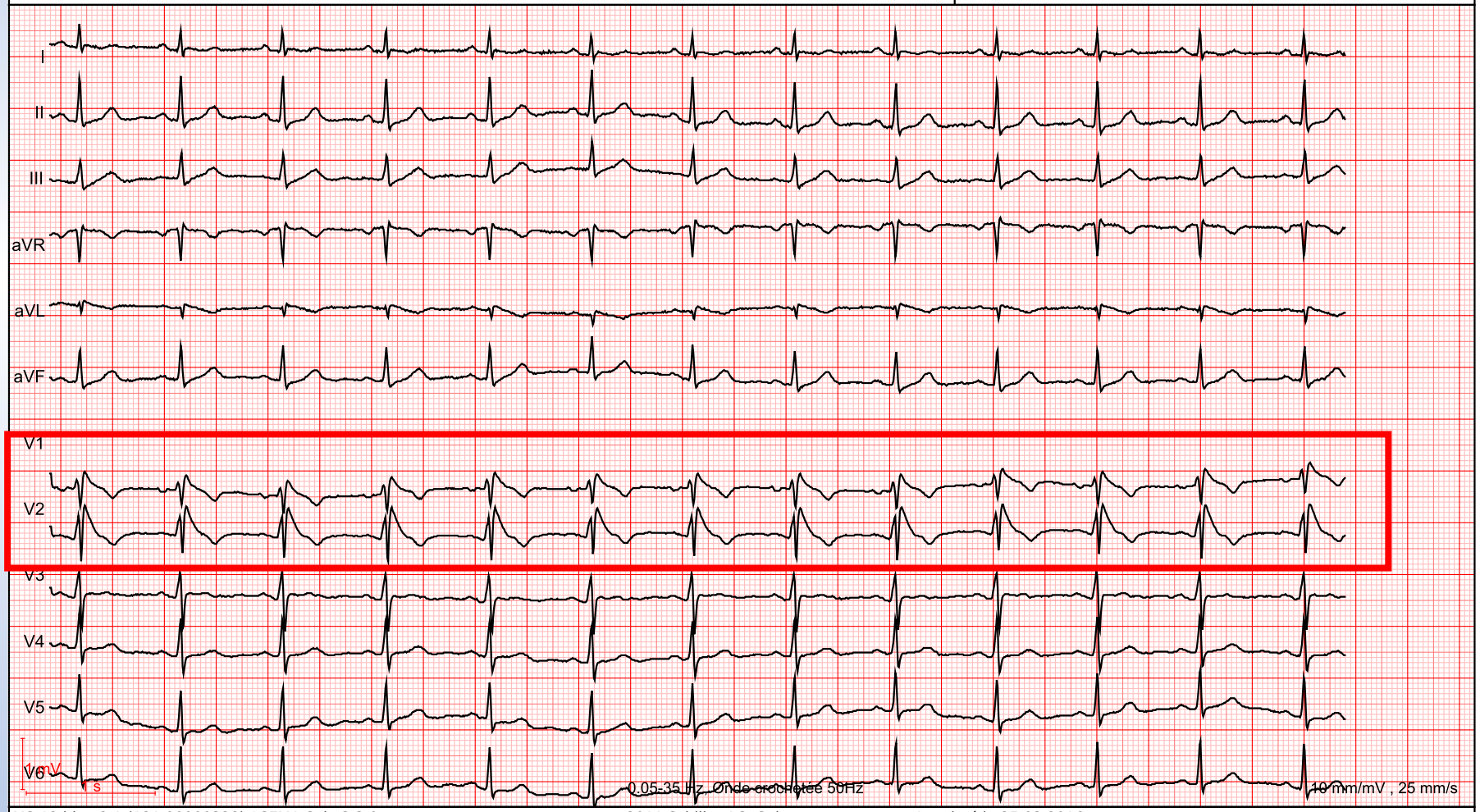

MS-12 blue 2.1 (121.00000328) / SEMA Solo 3.3.0 © 2011 Schiller AG, Suisse Imprimé le 25.03.2016 Page 1 de 1

J-Point Elevation in Survivors of Primary Ventricular Fibrillation and Matched Control Subjects

Incidence and Clinical Significance

JACC 2008

Raphael Rosso, MD,* Evgeni Kogan, MD,* Bernard Belhassen, MD,* Uri Rozovski, MD,* Melvin M. Scheinman, MD,§ David Zeltser, MD,* Amir Halkin, MD,* Arie Steinvil, MD,* Karin Heller, MD,* Michael Glikson, MD,† Amos Katz, MD,‡ Sami Viskin, MD*

Tel Aviv and Beer-Sheva, Israel; and San Francisco, California

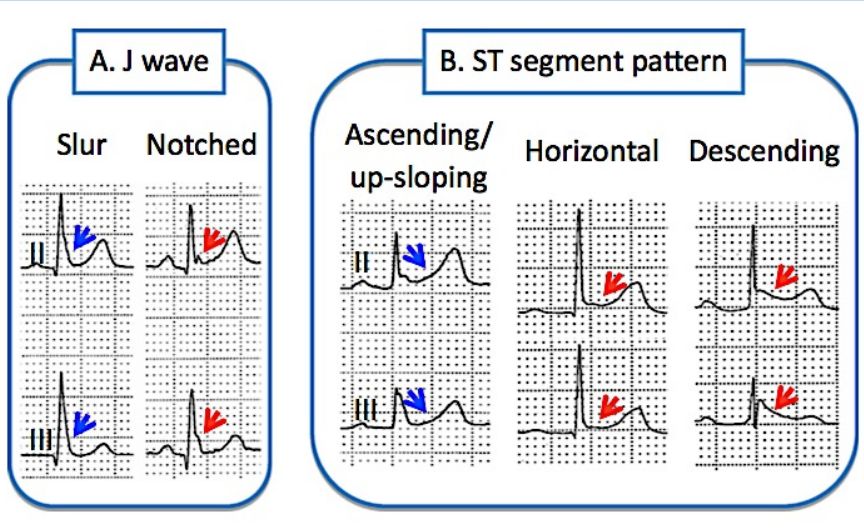

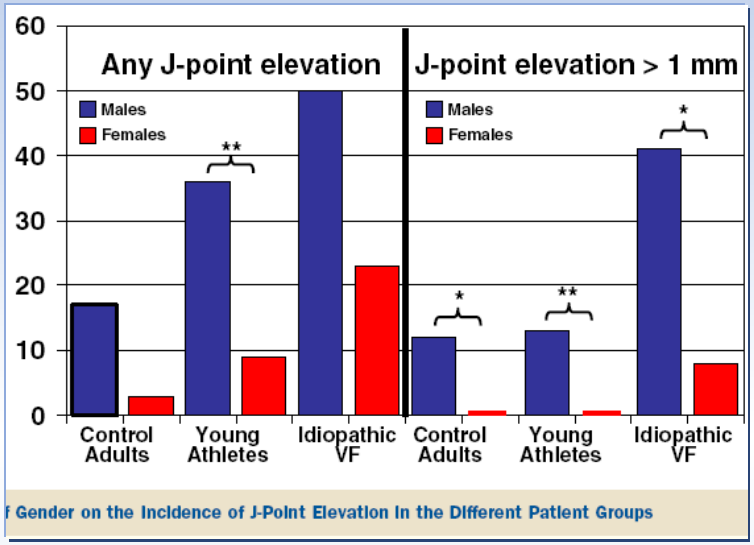

f Gender on the Incidence of J-Point Elevation in the Different Patient Groups

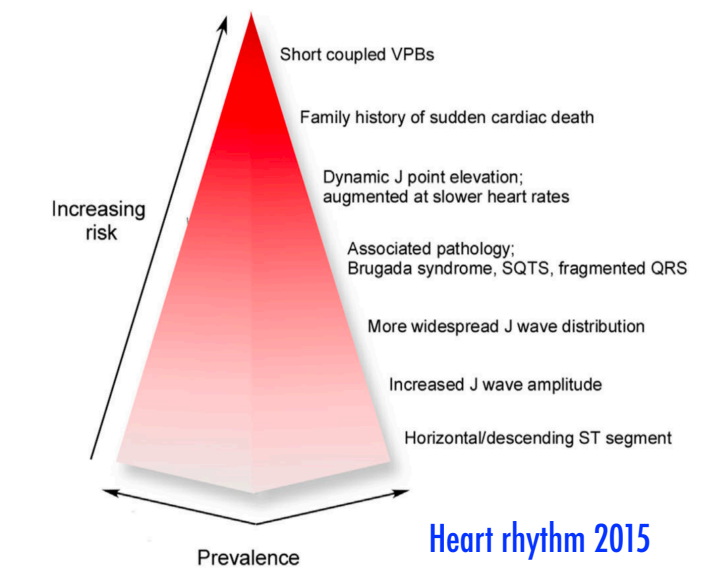

Heart rhythm 2015

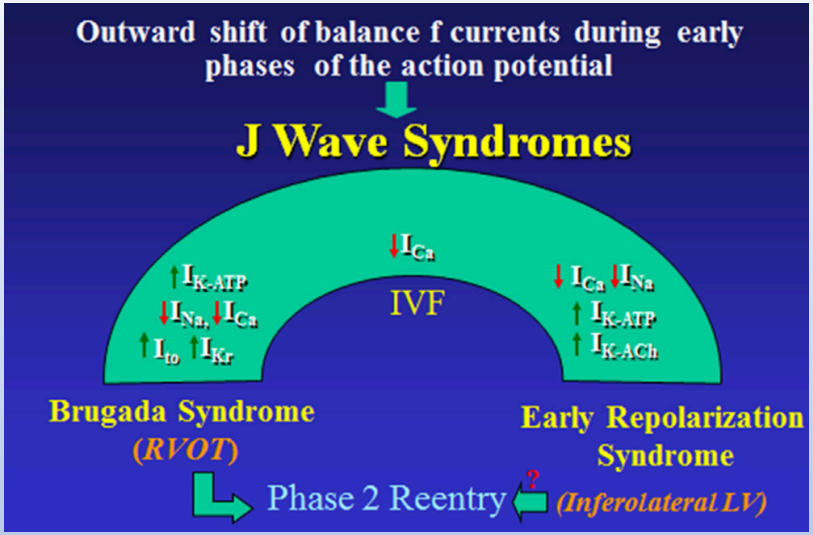

Early repolarization syndrome

Sexe:	M	**Axis**			
Taille:	0 cm	**P**	63°	**P**	138 ms
Poids:	0 kg	**QRS**	10°	**PQ**	196 ms
IMC:	--	**T**	39°	**QRS**	110 ms
PA:	--/--			**QT**	402 ms
				QTc (Bazett)	391 ms

Traitement méd.:

Demandé par :

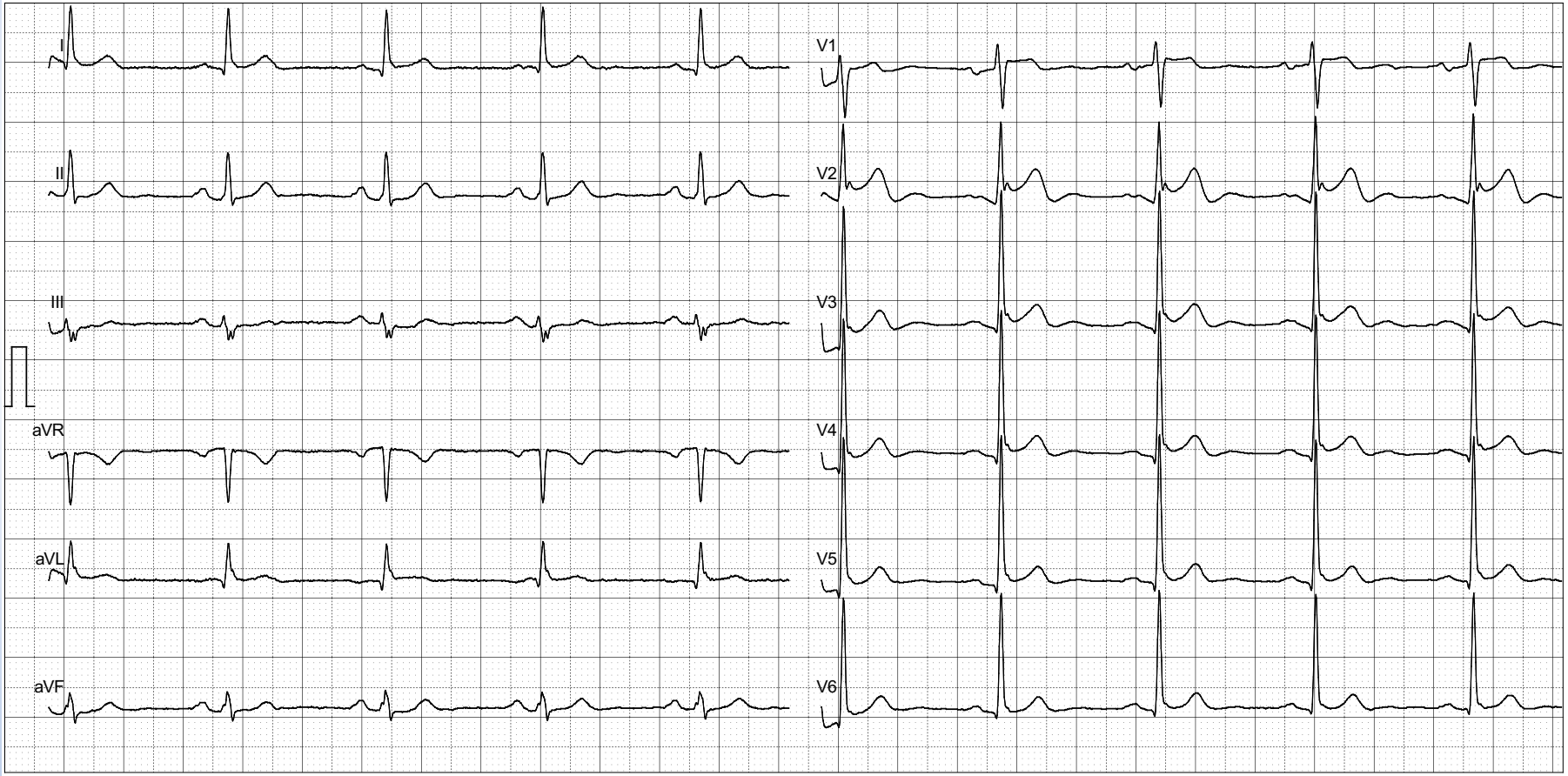

10 mm/mV 25 mm/s

Standard ARBA / 50Hz

ECG DE REPOS - SDS-200 Office V4.2.2, ETM 1.12.6 (c)2016 SCHILLER AG - Imprimé : 25.12.2017 12:21:10

10546

25.12.2017 12:20:57

LQT syndromes

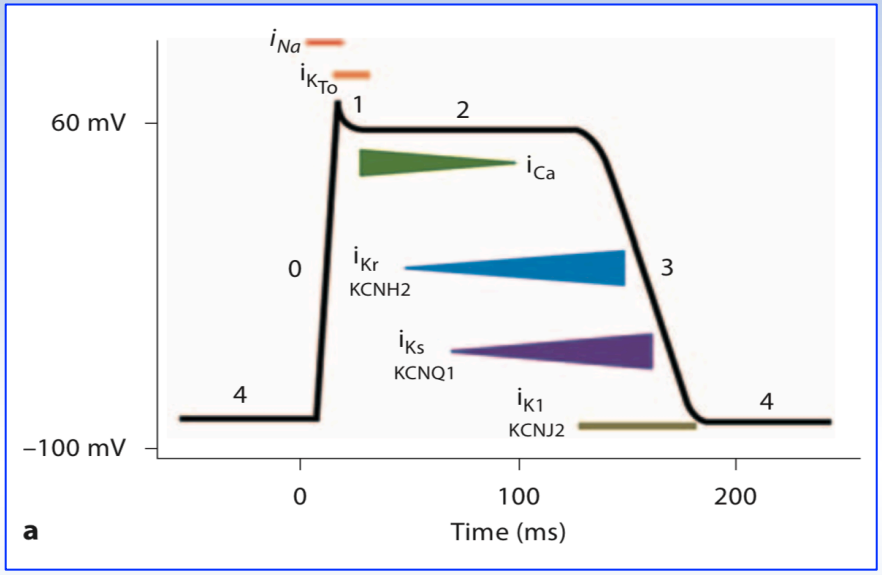

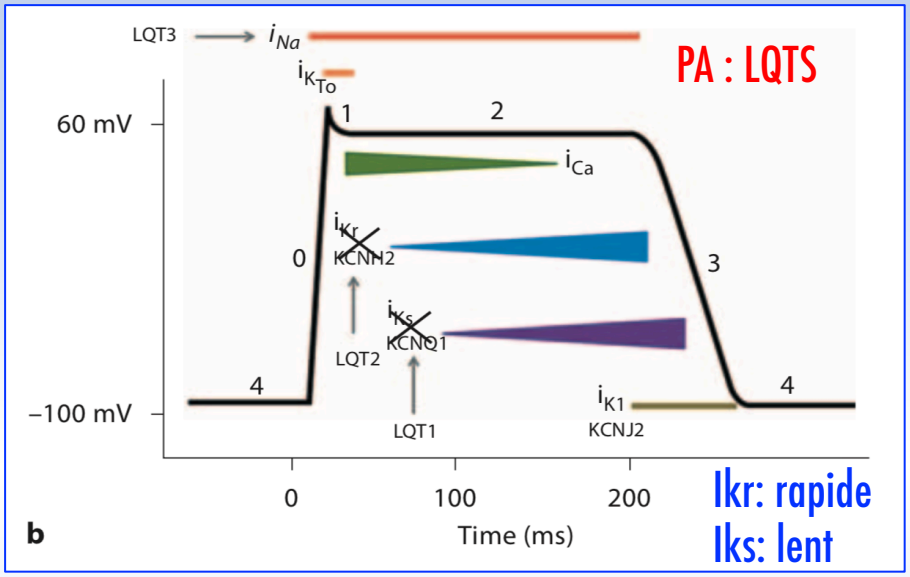

QTL	Gène	Protéine	Courant ionique	Fréquence
LQT1	KCNQ1	$K_V7.1\alpha$	$I_{Ks}\downarrow$	30-35 %
LQT2	KCNH2	$K_V7.11\alpha$	$I_{Kr}\downarrow$	25-30 %
LQT3	SCN5A	$Na_V1.5\alpha$	$I_{Na}\uparrow$	5-10 %
LQT4	ANK2	Ankyrin-B	$I_{Na,K}$, $I_{NCX}\downarrow$	1-2 %
LQT5	KCNE1	minKβ	$I_{Ks}\downarrow$	1 %
LQT6	KCNE2	MiRP1β	$I_{Kr}\downarrow$	Rare
LQT7*	KCNJ2	Kir2.1α	$I_{K1}\downarrow$	Rare
LQT8†	CACNA1C	$Ca_V1.2\alpha1c$	$I_{Ca,L}\uparrow$	Rare
LQT9	CAV3	Caveolin-3	$I_{Na}\uparrow$	Rare
LQT10	SCN4B	$Na_V1.5\beta4$	$I_{Na}\uparrow$	Rare
LQT11	AKAP9	Yotiao	$I_{Ks}\downarrow$	Rare
LQT12	SNTA1	A1-syntrophin	$I_{Na}\uparrow$	Rare

I_{Ca} : courant calcique entrant dépolarisant (lent) ; I_{K1} : Kir2.1 courant rectifiant entrant ; I_{Kr} : courant potassique sortant repolarisant rapide ; I_{Ks} : courant potassique sortant repolarisant lent ; I_{Na} : courant entrant sodique rapide ; *syndrome d'Andersen-Tawil ; †syndrome de Timothy

80%

Brenyo AJ et al. Cardiology 2012;122:237-247

LQT syndrome

QTc duration of more than 460 ms in children < 15 years of age, more than 450 ms in adult men, or more than 470 ms in adult women using the Bazett formula identifies QT prolongation.

The QT is best measured in lead II, lead V5, or lead V6

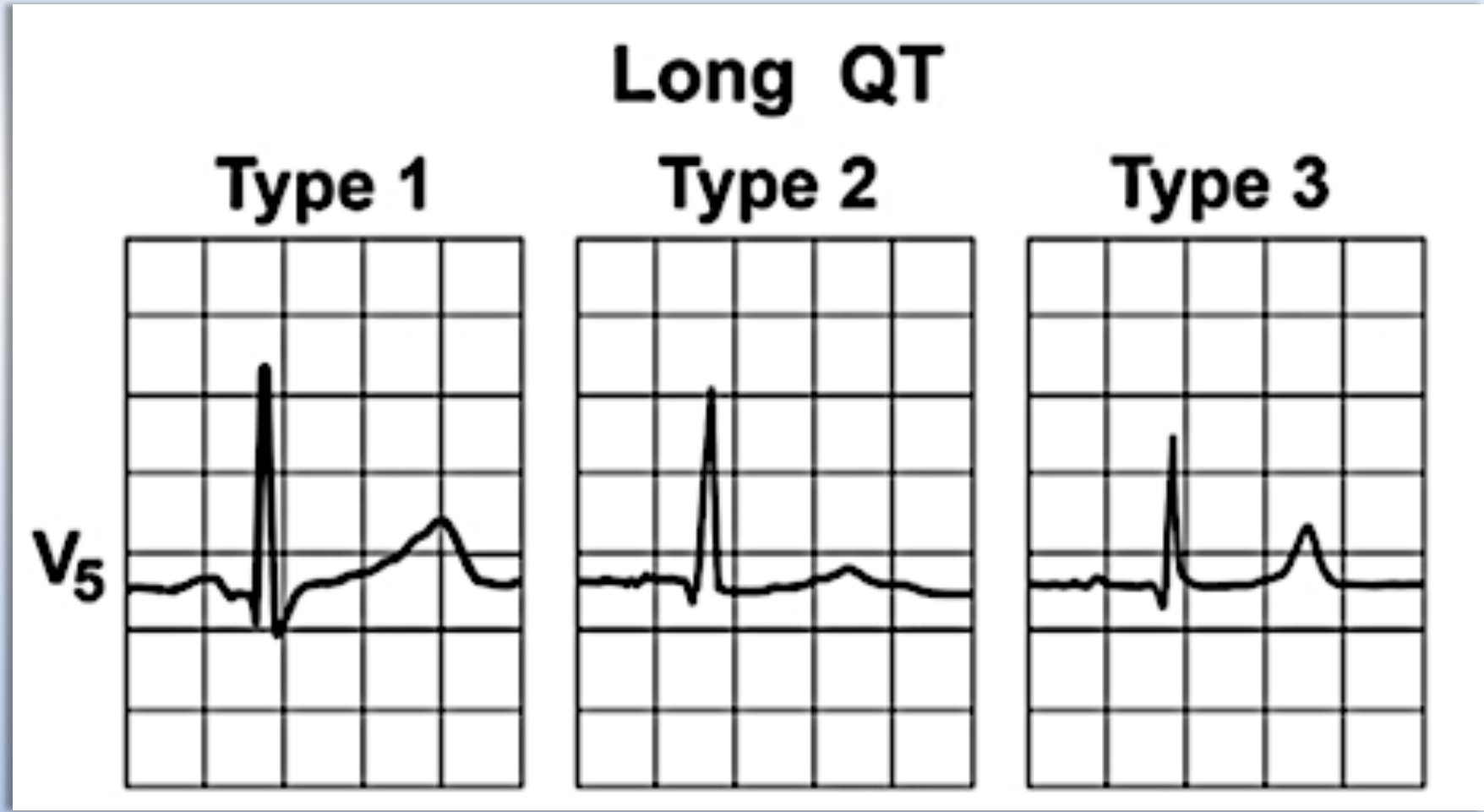

QTc duration

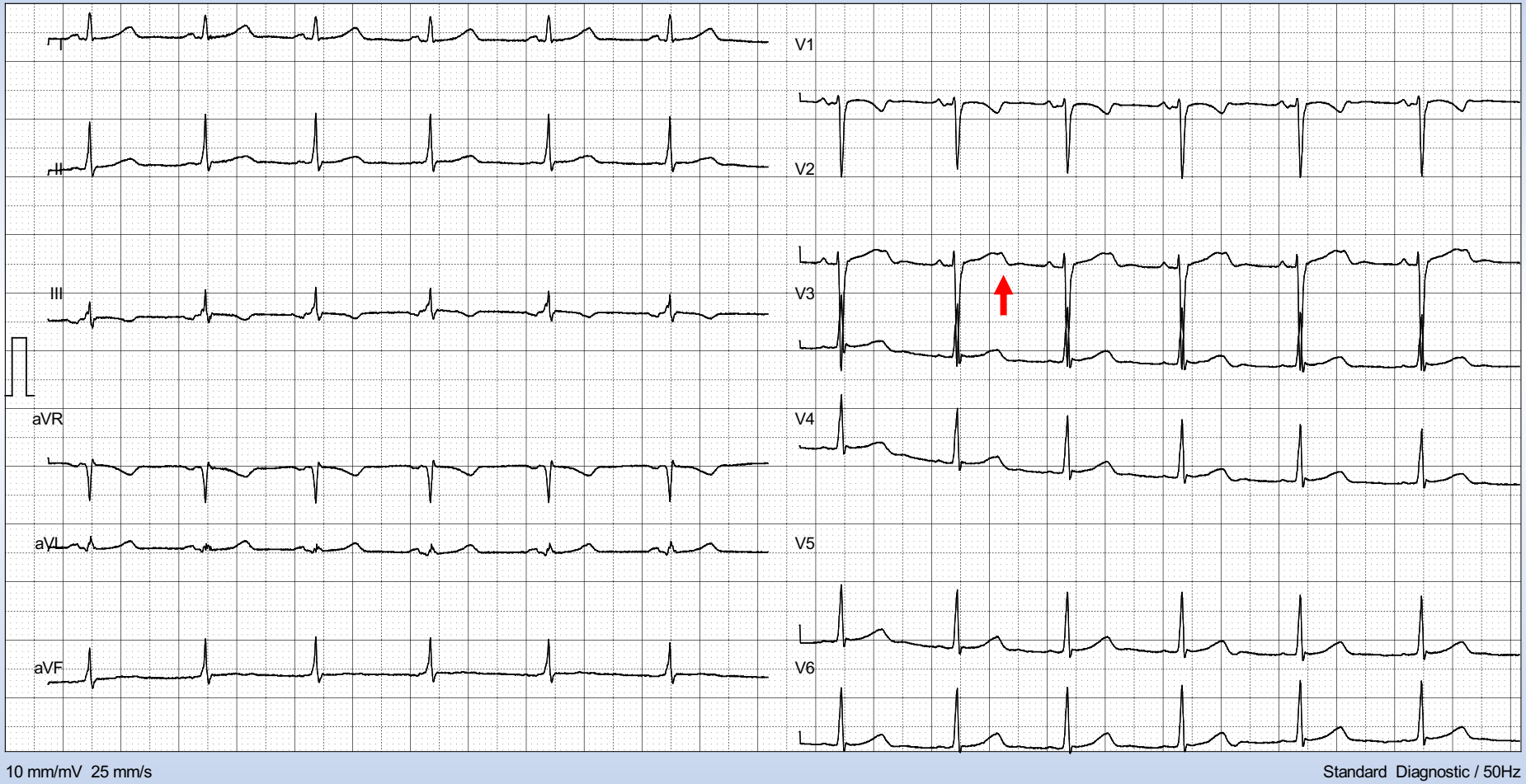

If you have U wave on T wave you must include it in the measurement

SQT syndrome

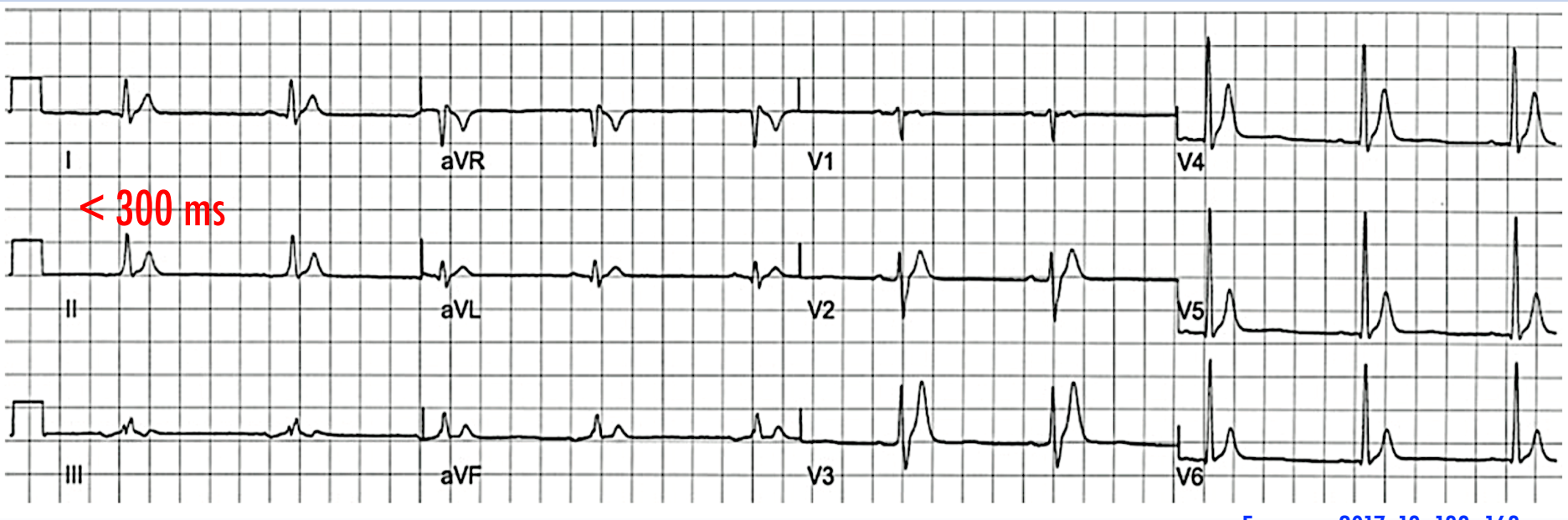

Europace 2017 .19, 139–163

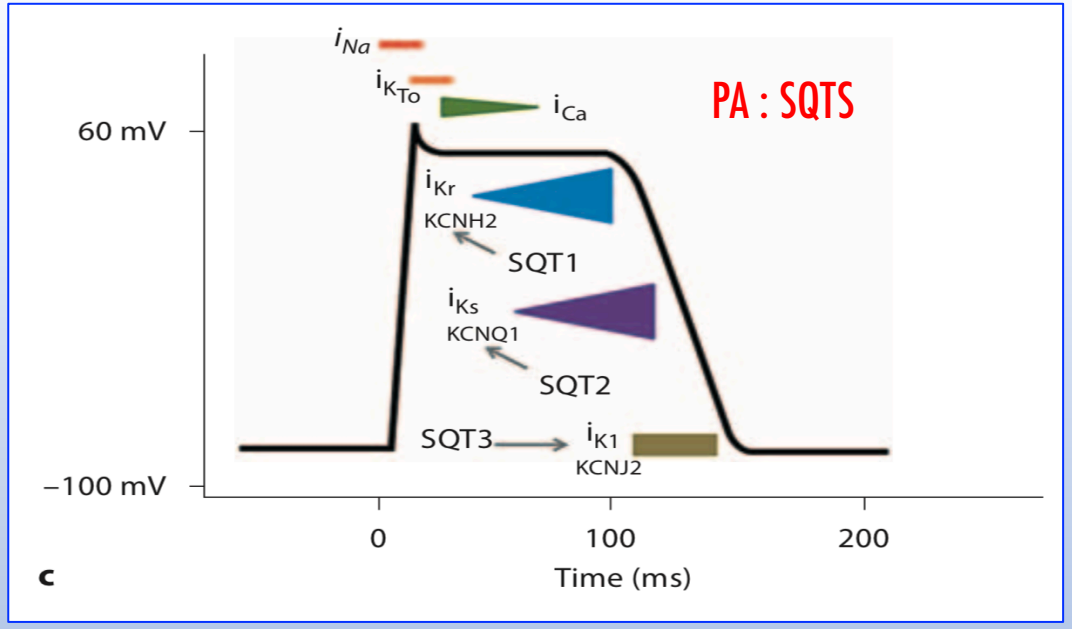

Premature ventricular beat

PVB: QRS morphology

More the QRS is "broad and dwarf", more we have heart disease...

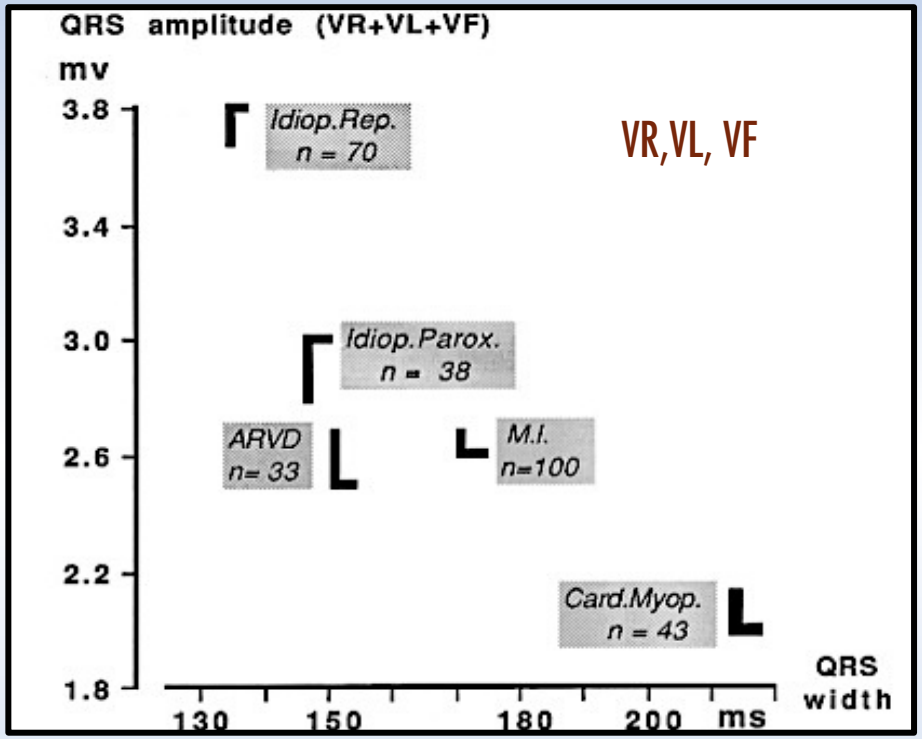

Ample (tall)
fine
late pouring
monomorphic
sinus QRS are normal

L'ESV bénigne est généralement ample et fine à couplage tardif monomorphe à type de retard gauche (à prédominance négative V1) et axe inférieur (positive en D2, D3 et AVF) (figure n°65). La transition du QRS précoce (V1-V2) ou tardive (V3-V4) renseigne sur la topographie respectivement droite ou gauche. Elle ne s'aggrave pas à l'effort et elle ne s'accompagne pas d'onde T négative de V1 à V3 sur les complexes QRS normaux. Ce dernier cas impose d'éliminer formellement une DAVD quand il est associé à des ESV.

A. Moustaghfir. ECG du sportif de haut niveau . 2018

More the QRS is "broad and dwarf", more we have heart disease...

Ample (tall) , fine, late pouring , monomorphic sinus QRS are normal

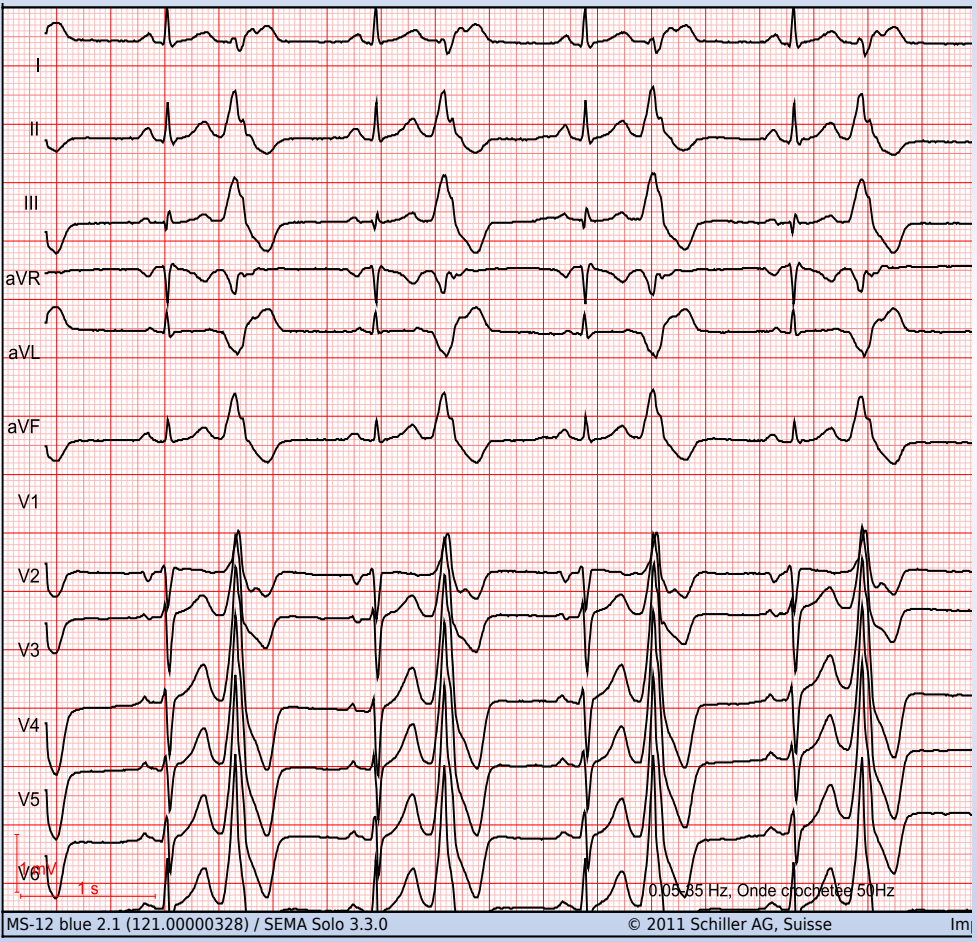

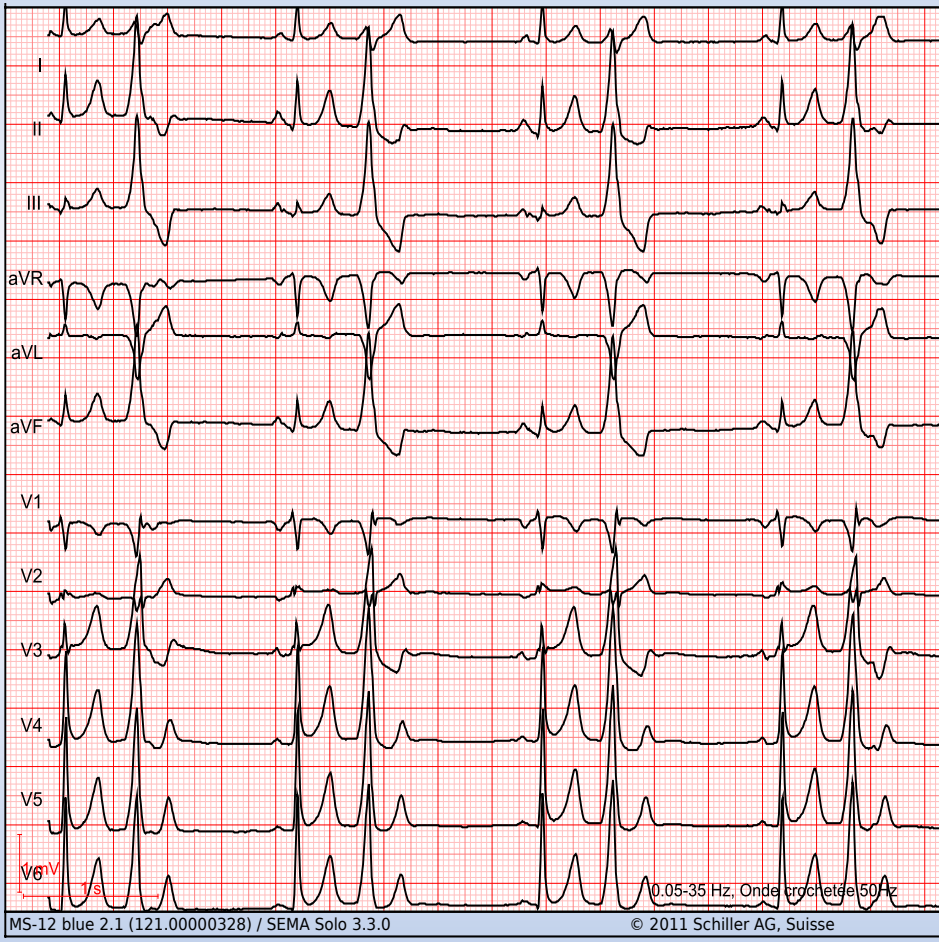

Ventricular tachycardia in bursts

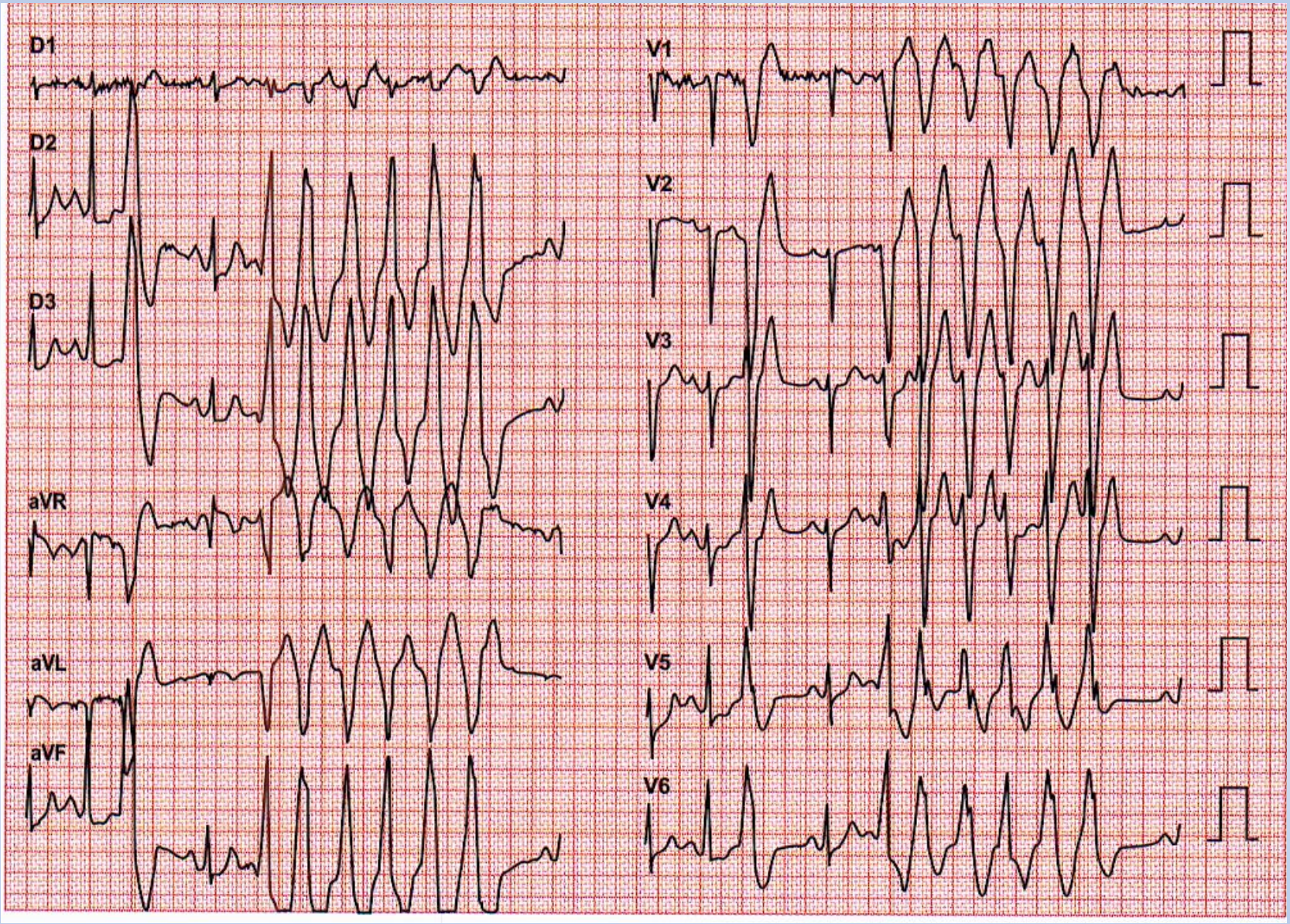

EXTRASYSTOLIE VENTRICULAIRE ET DYSPLASIE VENTRICULAIRE DROITE ARYTHMOGÈNE

ANALYSE CRITIQUE DE LA VALEUR DIAGNOSTIQUE DES EXAMENS NON INVASIFS

A. Moustaghfir, J.C. Deharo, L. Fourcade, J.P. Van de Walle, B. Mafart, P. Djiane, J.E. Touze

Presse Med 1996;25:546-8

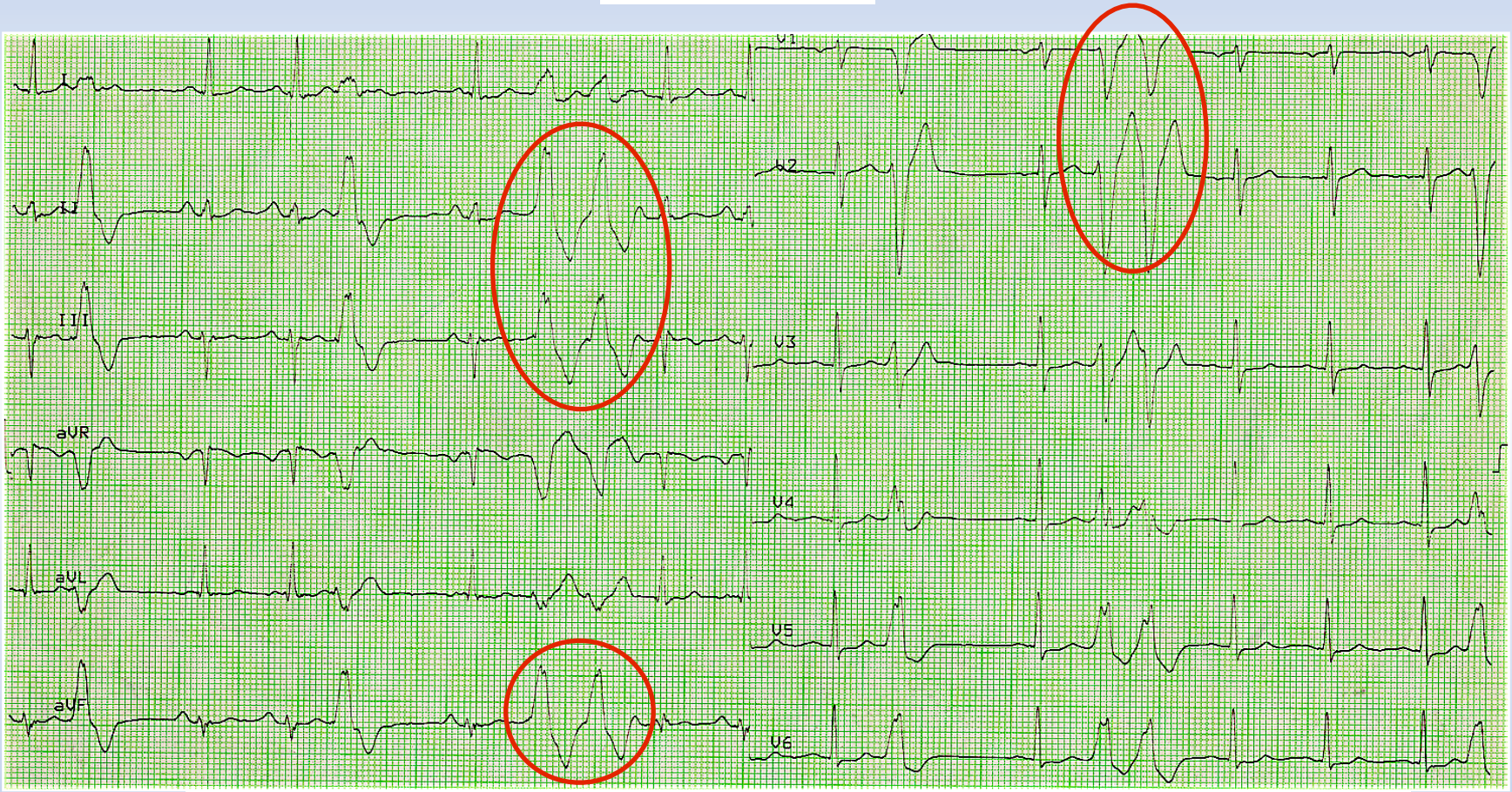

ESV : épreuve du temps! PVB: Test of time !

ESV infundibulaires ?

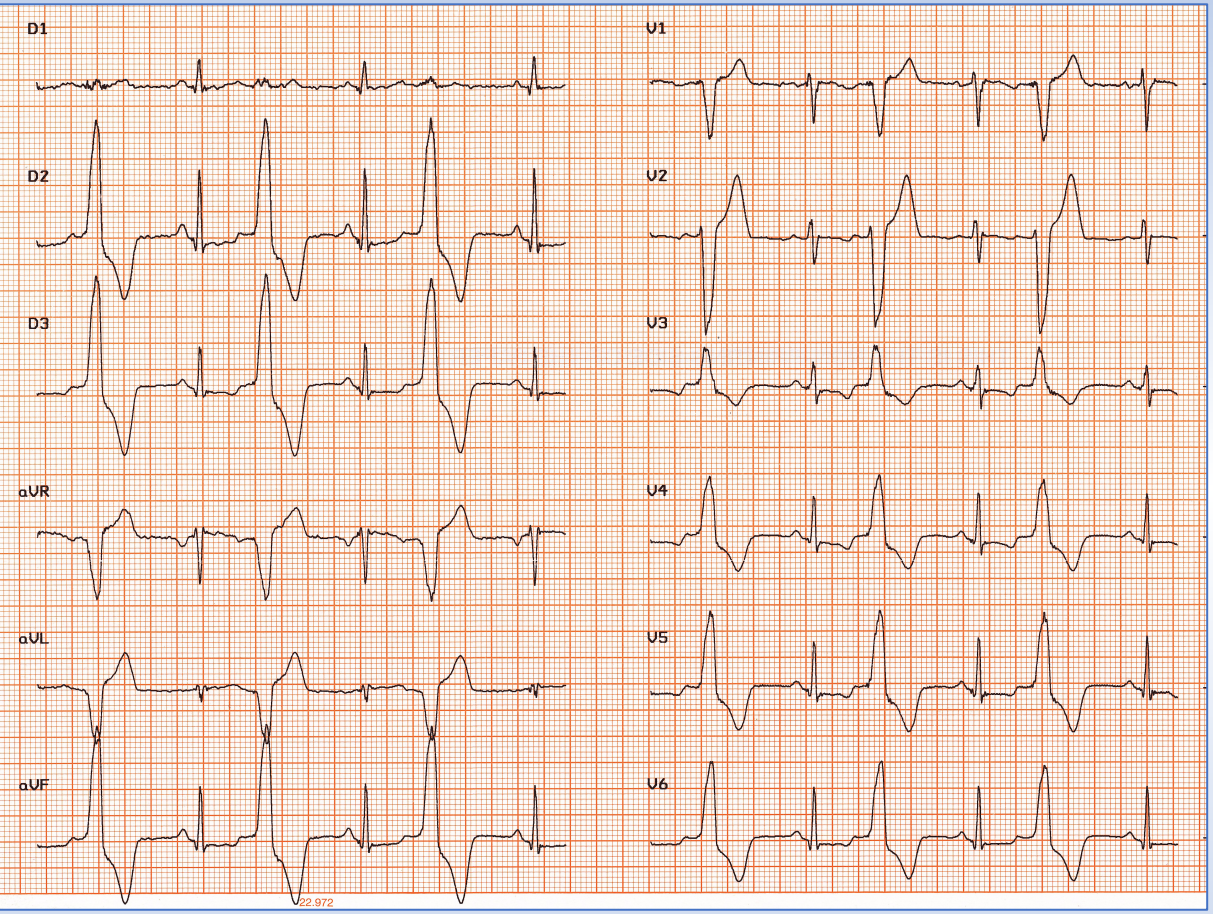

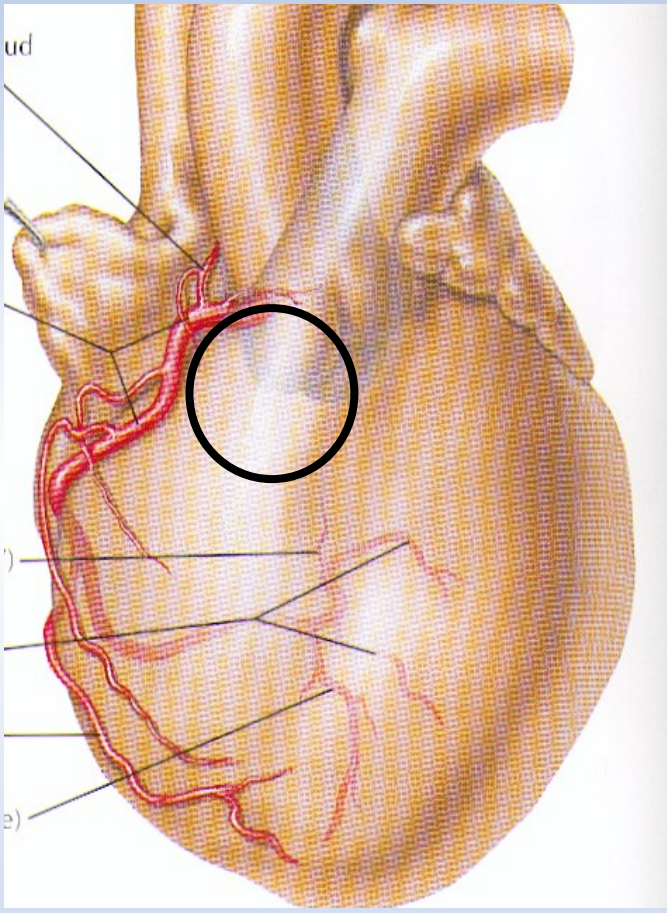

Exercise ECG

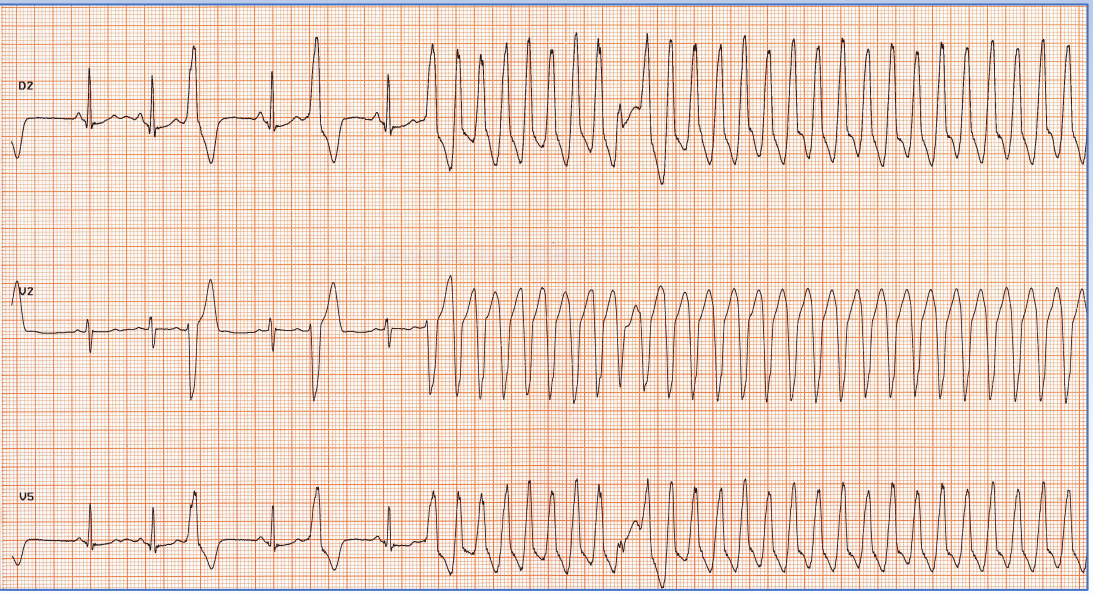

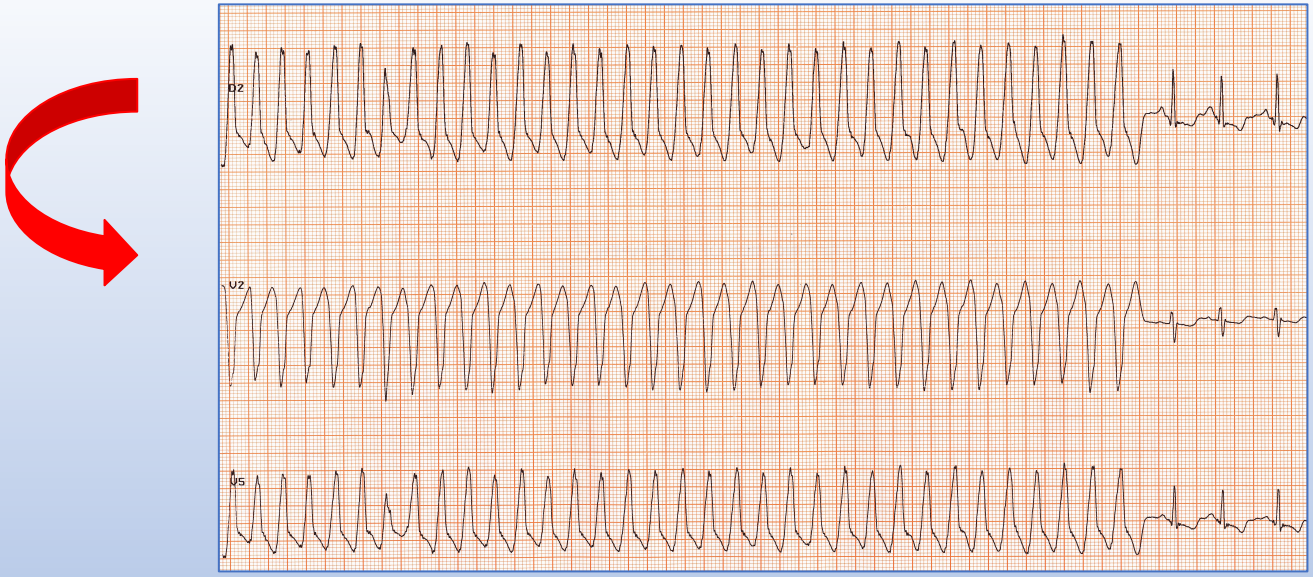

Review

How to evaluate premature ventricular beats in the athlete: critical review and proposal of a diagnostic algorithm

RMN +++

Domenico Corrado,[1] Jonathan A Drezner,[2] Flavio D'Ascenzi,[3] Alessandro Zorzi[1]

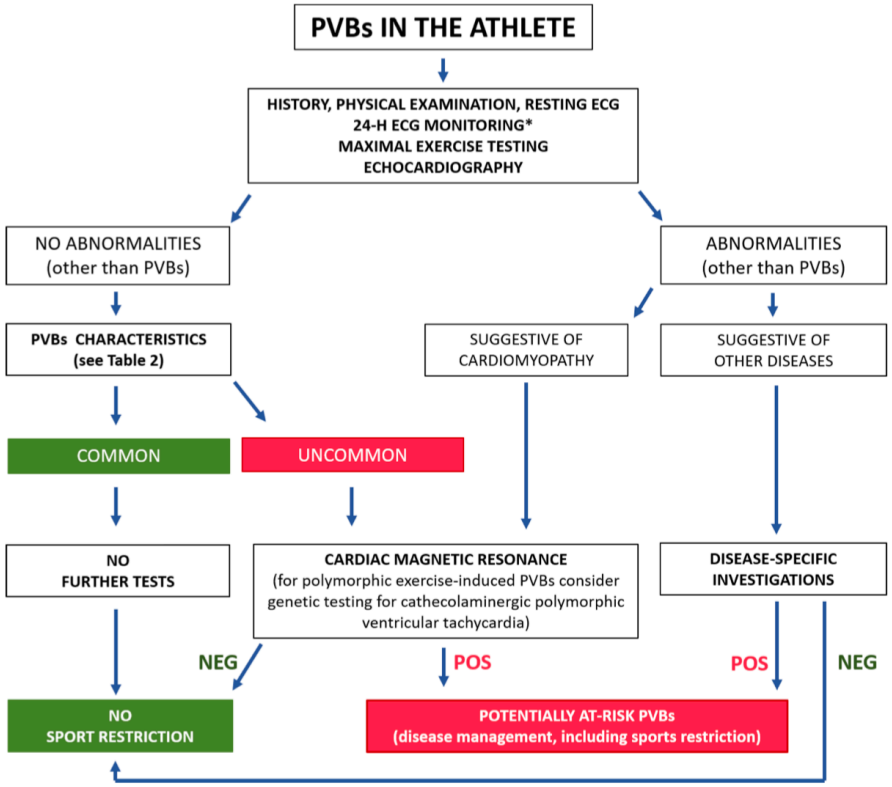

Figure 6 Proposed algorithm for evaluation of athletes with premature ventricular beats. *24-hour ECG monitoring should ideally have 12-lead configuration and include a training session. NEG, negative; POS, positive; PVBs, premature ventricular beats.

Table 3 Classification and risk stratification of premature ventricular beats in the athlete

	Common	Uncommon
PVB characteristics		
Ectopic QRS morphology	LBBB/inferior axis, typical RBBB and narrow QRS (<130 ms)	LBBB/intermediate or superior axis, atypical RBBB and wide QRS (≥130 ms)
Response to exercise testing	Decrease/suppression	Persistence/increase
Complexity of PVBs	Isolated, monomorphic	Repetitive‡, polymorphic
Short coupling interval*	No	Yes
Clinical findings		
Symptoms	No	Yes
Family history of premature SCD† or cardiomyopathy	No	Yes
Other ECG abnormalities	No	Yes
Imaging abnormalities	No	Yes

*PVBs are superimposed on the preceding T-wave peak or earlier (ie, R on T).
†Premature sudden cardiac death (SCD) is defined as that occurring before 40 years of age in men and before 50 years old in women.
‡Couplets, triplets or non-sustained ventricular tachycardia.
LBBB, left bundle branch block; PVBs, premature ventricular beats; RBBB, right bundle branch block.

Corrado D, et al. Br J Sports Med 2019

P « on » T wave : APB

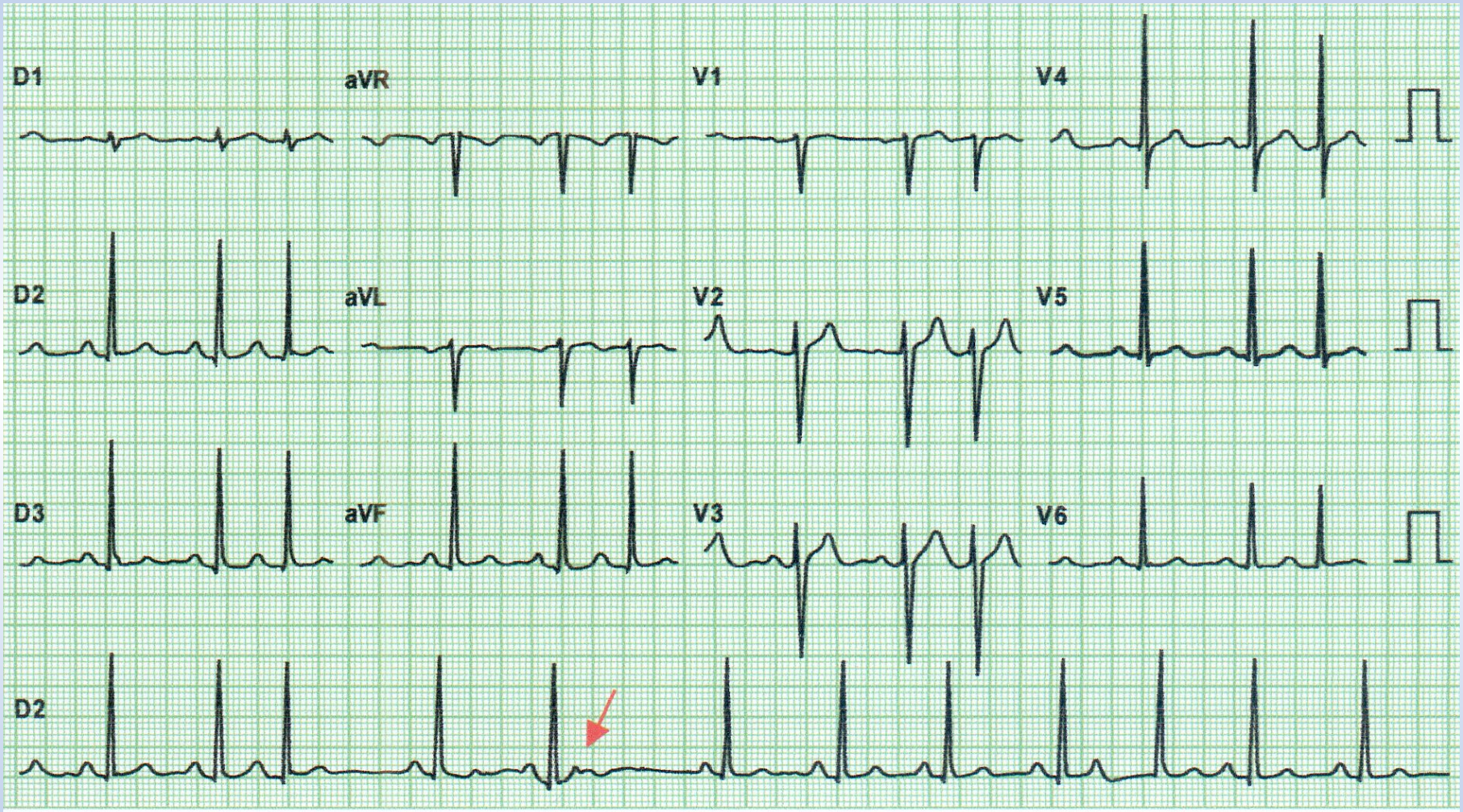

Atrial fibrillation and APB

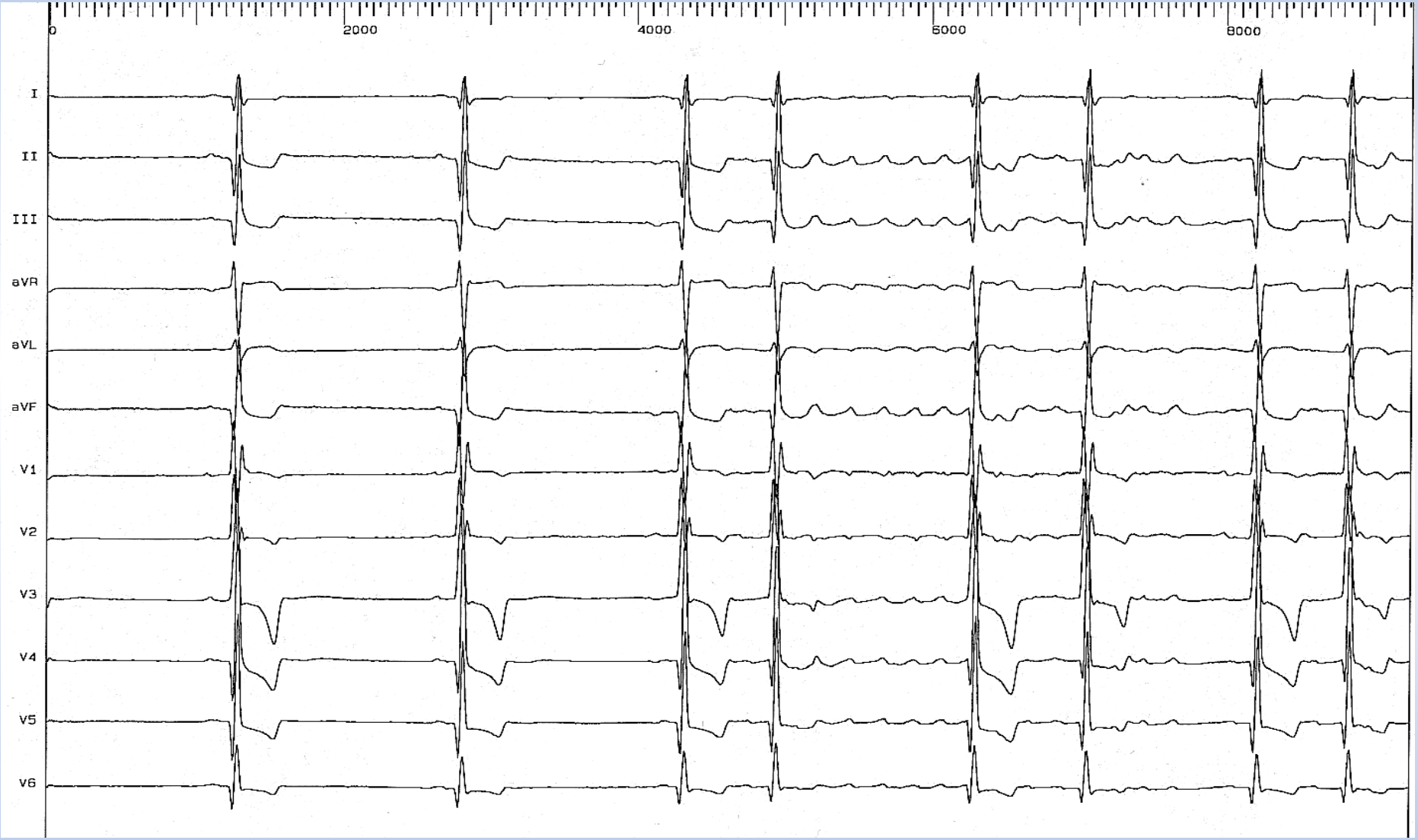

ECG and sport in Africa

Morocco 2002

ELSEVIER
Annales de cardiologie et d'angéiologie 51 (2002) 188–192
Annales de cardiologie et d'angéiologie
www.elsevier.com/locate/ancaan

Mémoire original

Cœur du sportif : modifications électriques et échocardiographiques au repos. Étude de 75 sportifs et de 45 témoins

Heart and sport modifications of electrocardiogram, late Potentiels and echocardiography about 75 sport's men and 45 whiteness

A. Moustaghfir [a,*], A. Hda [a], A. Benyass [a], M. Zahi [b], A. Boukili [a], V. Ohayon [c], A. Hamani [a], M.I. Archane [c]

Tableau 1
Principaux paramètres cliniques et électriques des deux séries

	Âge (années)	Poids (kg)	Taille (cm)	TA (mmHg)	FC (bat/min)	PR (ms)	QTc (ms)	Indice SL (mm)	Ondes T négatives (%)	Sus-décalage du Segment ST V2	Sus-décalage du Segment ST V3
Série témoins	25,75	68,2	174,35	127/65	69,93	155,33	373,04	28,27	6,60	1,13	1
Série sportifs	25,42	67,4	175,57	122/66	55,25	177,33	399,44	40,9	22,60	1,6	2
p	NS	NS	NS	NS	0,05	0,05	NS	< 0,0005	0,02	0,005	< 0,0005

Tableau 2
Principaux paramètres échocardiographiques des deux séries

	DTDVG (mm)	SIV (mm)	PPVG (mm)	Masse myocardique (g/m²)	OG (mm)	OD (mm)	VD (mm)
Témoins	49,37	8,32	8,96	97,13	31,34	36,34	23,06
Sportifs	53,39	10,32	10,71	148,4	37,7	45,38	28,03
p	NS	0,0125	0,025	0,005	0,025	0,0125	0,025

DTDVG : diamètre télédiastolique du ventricule gauche, SIV : septum interventriculaire, PPVG : paroi postérieure du ventricule gauche, OG : oreillette gauche, OD : oreillette droite, VD : ventricule droit.

African heart study

Algeria 2009

Br J Sports Med. 2009 Sep;43(9):716-21.

Cardiac findings in the precompetition medical assessment of football players participating in the 2009 African Under-17 Championships in Algeria.

Schmied C[1], Zerguini Y, Junge A, Tscholl P, Pelliccia A, Mayosi BM, Dvorak J.

OBJECTIVES:
To screen all players registered for the 8th CAF African Under-17 Championship for risk factors of sudden cardiac death.
DESIGN: Standardised cardiac evaluation prior to the start of the competition.
STUDY POPULATION: 155 male football players from all eight qualified teams; mean age 16.4 (SD 0.68) years (range 14 to 17).
METHODS: The cardiac evaluation consisted of a medical history, clinical examination, 12-lead resting electrocardiogram (ECG) and echocardiography, and was performed by three experienced cardiologists using established guidelines.
RESULTS: Nine (5.8%) players reported cardiac symptoms, and the clinical examination was abnormal in only two players with elevated blood pressure. A total of 40 players (25.8%) showed abnormal ECG patterns. None of the players with a positive ECG showed correlating echocardiographic findings. The echocardiogram of one player appeared highly suspicious for early-stage hypertrophic cardiomyopathy, and in another player the myocardium was suspicious for non-compaction cardiomyopathy, but both had normal ECGs. **Thirteen (8.4%) players showed echocardiographic findings that needed further follow-up**. The percentage of players with pathological ECG patterns and some abnormal echocardiographic measurements varied substantially between different ethnic groups.
CONCLUSION:
Cardiological screening for risk factors of sudden cardiac death of football players prior to an international competition proved feasible, and conduction by independent experts allowed high-quality standards and a consistent protocol for the examinations. Differences observed between ethnic groups indicate that guidelines for the analysis of ECGs and echocardiography might be adjusted to the target population.

Tunisia 2007

ELSEVIER MASSON
ScienceDirect
Science & Sports 22 (2007) 78–86
SCIENCE & SPORTS
http://france.elsevier.com/direct/SCISPO/

Article original

Analyse de l'électrocardiogramme et de l'échocardiographie de 181 footballeurs professionnels tunisiens

Electrocardiographic and echocardiographic analysis of 181 tunisian professionals football players

H. Ouldzein[a,*], F. Azzouzi[b], D. Ayadi-Koubaa[b], Z. Bartagi[b], R. Cherradi[a], R. Mechmeche[c]

Principaux aspects électrocardiographiques chez le sportif selon les auteurs

Variables	Pelliccia [26] *n* = 1005 %	Sharma [32] *n* = 1000 %	Somauroo [34] *n* = 171 %	Notre étude *n* = 181 %
Aspect d'hypertrophie ventriculaire gauche		45	50	3,3
Hypertrophie auriculaire gauche	0,9	14	0	2,8
Hypertrophie auriculaire droite	0,2	16	1,8	0,6
Ondes T négatives	2,7	4	11,2	7,2
Sus-décalage de ST	14,3	43	1,2	3,9
Onde Q ≥ 2 mm	8,6	0	0,6	5,0
Bloc de branche droit complet	0,2	0,6	0,6	1,7
Bloc de branche droit incomplet	12,1	29	5,3	7,2
Bloc de branche gauche incomplet	0,2	0	0	1,7
Bloc auriculoventriculaire du premier degré	7,5	5		4,4
Bloc auriculoventriculaire du 2e degré Mobitz	0	0,2	0	0
Bloc auriculo-ventriculaire du 3e degré	0	0	0	0
Bradycardie sinusale < 60 battements/mn	36,4	80	39,0	40,9
Onde Delta	0,3		0,6	0
PR court sans onde delta	0,9		1,2	0
QTc allongé		0,03	0	3,9

African heart study

Gabon 2013

Br J Sports Med. 2013 Jun;47(9):579-84.

Screening athletes for cardiovascular disease in Africa: a challenging experience.

Schmied C[1], Di Paolo FM, Zerguini AY, Dvorak J, Pelliccia A.

Abstract
AIMS:
Preparticipation cardiovascular (CV) screening has been advocated as an efficient strategy to reduce sudden cardiac death in Caucasian athletes. At present, uncertainty remains if such strategy is feasible and efficient in native African athletes. To this scope, we performed a CV screening in an African setting.
METHODS: 210 male Gabonian football players were examined with history, physical examination, ECG and echocardiography.
RESULTS:
On history, 19 players (9%) referred atypical chest discomfort/oppression. Familial sudden death was referred by 36 (17%). No anomalies were detected at physical examination. ECG showed large proportions of 'training-related' abnormalities, that is, ST-segment elevation in precordial leads in 150 (71.4%), and isolated increase in R/S-wave voltage in 116 (55.2%). A substantial subset (12.4%) showed 'training-unrelated' abnormalities, that is, inverted T-waves in 10 (4.8%), left atrial enlargement in 8 (4%), deep Q-waves in 3 (1.4%). On echocardiography, one athlete meet criteria for hypertrophic cardiomyopathy (HCM); none showed evidence for arrhythmogenic right ventricular cardiomyopathy (ARVC) or dilated cardiomyopathy (DCM). Other abnormalities included mitral valve prolapse in three, atrial septal defect in two and pulmonary hypertension in one.
CONCLUSIONS:
About 12% of native African athletes showed ECG abnormalities unrelated to training and requiring additional testing and periodical follow-up. Structural abnormalities were found, however, **in a minority (5%), including HCM in one, but no ARVC or DCM.** In conclusion, this study demonstrates that preparticipation CV screening is efficient to identify (or raise suspicion) for CV abnormalities in native African athletes, but challenging for conclusive identification of cardiac diseases in the difficult scenario of a developing Africancountry.

my friend Dr Mouyopa did not have his name on this article

Practical questions in Africa?

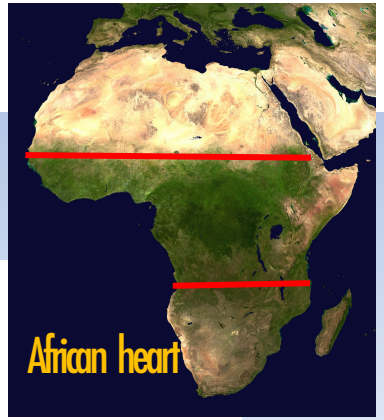

Learn to work together?

ECG and echocardiographic criteria?

Definition of an athlete's heart: black and white?

Etiology of sudden death in Africa: climate, valve disease and infections +++

What prevention strategy in Africa?

Screening in schools +++++

Screening strategy

Préface du Pr. Pascal DEFAYE
CHU Grenoble-France

L'ÉLECTROCARDIOGRAMME

du sportif de haut niveau

Aspects normaux, pathologiques et particularités africaines

Pr. Abdelhamid MOUSTAGHFIR

de l'adaptation à l'entrainement physique
au risque de mort subite

Engager des études propres à nous sur une grande échelle de sportifs africains est une urgence stratégique. Ce n'est que comme ça qu'on pourra mieux tenter d'établir les limites entre le normal et le pathologique dans notre continent et de mieux appréhender les causes des morts subites et donc mieux les prévenir.

Abdelhamid MOUSTAGHFIR

Initiate own studies to us on a large scale African sports is a strategic emergency.
Only how we can better try to establish the boundaries between normality and pathology in our continent and to better understand the causes of sudden death for Prevention

ISBN : 978-9954-9075-04
Impression : El Baraka Graph